

Carotid intima-media thickness at different locations: Association to coronary heart disease in patients with heart valve disease

Joanna de Zayas Galguera[✉], MD; Aylen Pérez Barreda, MD; Francisco Vázquez Castro, MD; Ronald Aroche Aportela, MD; Katia Ravelo Llanes, MD; and Myder Hernández Navas, MD

Department of Cardiology. Medical-Surgical Research Center (CIMEQ [Centro de Investigaciones Médico-Quirúrgicas]). Havana, Cuba.

Este artículo también está disponible en español

ARTICLE INFORMATION

Received: October 20, 2017
Accepted: November 16, 2017

Competing interests

The authors declare no competing interests

Acronyms

CCA: common carotid artery
CIMT: carotid intima-media thickness
ECA: external carotid artery
ICA: internal carotid artery

ABSTRACT

Introduction: The atherosclerosis is a generalized disease of the arterial wall. The carotid intima-media thickness (CIMT) has shown an association with cardiovascular risk factors and the prevalence of cardiovascular disease. The carotid ultrasound protocols differ considerably from one another.

Objective: To compare the value of the CIMT measured in several anatomical locations for the diagnosis of significant coronary disease.

Method: A total of 62 patients scheduled for valve replacement surgery with previous conventional coronary angiography (invasive) were studied. Before the surgery, the measurement of the CIMT was made in the common carotid artery (CCA), the bulb and in the internal carotid artery (ICA) through ultrasonography. The association among each of these variables, as well as the sensitivity, specificity and positive and negative predictive values were determined.

Results: Only 9 of the 62 patients studied had significant coronary lesions. It was observed that for values of similar sensitivity and specificity in the carotid segments studied, a higher cut-off value of CIMT was required in the bulb (0.87 mm) and even more in the ICA (0.98 mm), in relation to the CCA (0.71 mm), thus, the latter represents the method with the highest diagnostic value in the patients studied.

Conclusions: The group of patients with significant coronary lesions showed values of CIMT in each of the explored locations greater than the group without coronary lesions. The CCA was the place where the best visualization of the CIMT was obtained, and where acceptable validity parameters were achieved, as well as a good correlation with the coronary atherosclerosis of these patients.

Keywords: Intima-media thickness, Carotid Artery, Coronary artery disease, Myocardial ischemia, Ultrasonography

Grosor íntima-media carotídeo en diferentes sitios: Relación con la enfermedad coronaria en pacientes con valvulopatías

RESUMEN

Introducción: La aterosclerosis es una enfermedad generalizada de la pared arterial. El grosor íntima-medio carotídeo (GIMC) ha mostrado asociación con los factores de riesgo cardiovascular y con la prevalencia de enfermedad cardiovascular. Los protocolos de ultrasonido carotídeo difieren entre sí considerablemen-

[✉] J de Zayas Galguera
CIMEQ. Calle 216 y 11B. Rpto.
Siboney, Playa, CP 12100.
La Habana, Cuba.
E-mail address:
joannadezayas@infomed.sld.cu

te.

Objetivo: Comparar el valor del GIMC medido en varios sitios anatómicos para el diagnóstico de enfermedad coronaria significativa.

Método: Se estudiaron 62 pacientes programados para cirugía de sustitución valvular con previa realización de coronariografía convencional (invasiva). Antes de la cirugía se realizó la medición del GIMC en la arteria carótida común (ACC), el bulbo y en la carótida interna (ACI) a través de ultrasonografía. Se determinó la asociación entre cada una de estas variables, la sensibilidad, especificidad y los valores predictivos positivos y negativos.

Resultados: Sólo 9 de los 62 pacientes estudiados tuvieron lesiones coronarias significativas. Se observó que para valores de sensibilidad y especificidad similares en los segmentos carotídeos estudiados se necesita un valor de corte mayor de GIMC en el bulbo (0,87 mm) y más aún en la ACI (0,98 mm), en relación con la ACC (0,71 mm), por lo que este último constituye el método de más valor diagnóstico en los pacientes estudiados.

Conclusiones: El grupo de pacientes con lesiones coronarias significativas mostraron valores de GIMC en cada uno de los sitios explorados mayores que el grupo sin lesiones coronarias. La ACC fue el sitio donde mejor visualización se tuvo del GIMC, y donde se lograron parámetros de validez aceptables, así como buena correlación con la aterosclerosis coronaria de estos pacientes.

Palabras clave: Grosor íntima-media, Arteria carótida, Enfermedad arterial coronaria, Isquemia miocárdica, Ultrasonografía

INTRODUCTION

The atherosclerosis is a chronic inflammatory process that affects the arteries of different vascular layers and which is characterized by the thickening of the intima and media layers with loss of their elasticity. Its basic lesion is the atherosclerotic plaque composed mainly of lipids, fibrous tissue and inflammatory cells, and it goes through different stages¹. Several are the clinical manifestations produced by atherosclerosis, among the most frequent are: brain infarctions, ischemic transient accidents, peripheral arterial failure and ischemic heart disease^{2,3}.

About 7 million people die every year in the world from coronary heart diseases and 1.3 million more suffer from non-fatal myocardial infarction. The mortality rate due to the ischemic disease in Cuba for men and women in 2012 was 139.1 and 133.7 per 100 thousand inhabitants respectively⁴. Therefore, the demographic, health and social impact of these diseases is increasing and will continue to do so in the coming decades.

Over recent years, a breakthrough in imaging techniques has taken place, that allows the visualization and characterization of atherosclerotic plaques, and their progression or regression. In addition, once the disease is detected in a territory, it can be assumed that all territories are affected, given the diffuse nature of this disease. The early detection of

atherosclerosis would allow the application of new opportunities in primary prevention, either through the modification of lifestyle or even through pharmacological therapy, especially for patients with an intermediate pre-test cardiovascular risk⁵.

The carotid intima-media thickness (CIMT) allows detecting the arterial wall thickening in early stages of the atherosclerosis before the light affection takes place. It has been shown that the CIMT is related to the impact and prevalence of atherosclerosis in all its clinical forms, and also, with the cardiovascular risk factors⁶.

Numerous studies support the use of the CIMT measurement as a marker of subclinical and systemic atherosclerosis. According to Lahoz and Mostaza⁷, several studies have certified the value of this method in its evaluation, stratification and decision making concerning therapeutic behaviors. The CIMT has well established efficacy and there are relatively uniform definitions about it. This is an advantage in the research of large populations, in which a large part of the participants does not have atheromatous plaque in the carotid. It is a cheap, easy, safe and reproducible method that has become an important tool for prevention strategies, diagnosis and treatment of the atherosclerotic disease⁷.

The technique has also shown an important role in controlling the progression, stabilization and regression of atherosclerosis with the lipid lowering

and antihypertensive therapy, as well as the treatment of other coronary risk factors⁷.

Currently, the determination of the cut-off value of the CIMT with which the coronary atherosclerotic disease is associated remains to be a subject to debate⁷. Proof of this is found in the works published by different authors, such as the study conducted by Velasco del Castillo *et al.*⁸, where they show as reference values, 0.71 mm for men and 0.67 mm for women. In another work, published in 2013 by Folsom *et al.*⁹, is proposed as a result, an optimal CIMT's cut-off point of 0.83 mm as mean value and 1.01 mm as the maximum value, to discriminate the presence or absence of coronary heart disease with a coronary calcium score greater than zero.

Nowadays, the carotid ultrasound protocols differ considerably from one another. The CIMT of the common carotid is a marker and predictor of some of the cardiovascular risk factors. However, there are anatomical and pathological reasons of weight to consider the combined intima-media thickness of the three anatomical segments (common carotid artery, bifurcation or carotid bulb and internal carotid artery) as a marker and more effective predictor¹⁰.

The different protocols include one, two or the three carotid segments mentioned before. Furthermore, there can only be measured the diffuse raise of the intima-media complex's thickness and exclude areas with plaque, or include the plaque's thickness as part of the CIMT. It is also possible to measure only the far or posterior walls of the common carotid artery or the three carotid segments; or to measure the near or anterior walls, and the far or posterior walls, and average them¹¹. Most studies use the right and left carotids and average values of both, but there are some that use the right carotid¹².

In the measurement of the common carotid's CIMT, very reproducible, the measurement of the atheromatous plaques' thickness of the distal third can be included, an unusual place of localization, that is why most studies do not include them. However, other authors prefer the joint assessment of the CIMT of the common carotid and the bifurcation, because these expose the poor correlation of the CIMT of the first, with the risk factors and cardiovascular diseases. Other works also used the CIMT at the level of the bifurcation because it has a hemodynamic situation similar to that of the coronary tree (flow separation and shear stress), with more frequent localization of plaques at this level^{10,12}.

On the other hand, to the combined CIMT is objected the difficulty of visualizing the internal carotid

artery, with the possibility of not visualizing any wall and not carrying out a complete assessment. However, the results of more recent studies show a positive evolution of the measurement at the level of the internal carotid artery, with an increase in its reproducibility from <0.75 ¹³ to > 0.85 ¹⁴. The OPAL study shows a feasibility of viewing all the segments above 90%.

Considering the above, there was decided to conduct a study to determine the diagnostic value and to compare the values of CIMT measured in different areas of the carotid, and to relate the presence of lesions in the coronary arteries in patients with heart valve disease, prior to valve replacement surgery.

METHOD

An observational descriptive and cross-sectional study was conducted in patients undergoing valve replacement surgery at the Department of Cardiology of the Medical-Surgical Research Center (CIMEQ [*Centro de Investigaciones Médico-Quirúrgicas*]), from June 2015 to June 2016.

The population consisted of all patients admitted to the Department of Cardiology, diagnosed with heart valve disease, to have surgical treatment, and who met the selection criteria.

Inclusion criteria

- Male and female patients scheduled for elective valve surgery.
- Patients with coronary angiography previously performed.
- Patients who approved to participate in the study.

Exclusion criteria

- Previous coronary revascularization.
- Ischemic heart disease confirmed.
- Patient refusal to participate in the research.

The sample consisted of 62 patients of the total of those admitted, due to the impossibility of performing all the corresponding examinations.

Protocol of carotid ultrasound

The study was performed using a sonographer Philips iE33 with high frequency linear transducer (L11-3) for vascular studies with focus depth between 30 and 40 mm, photogram optimal speed at 25

Hz, with optimization of the gain to achieve higher quality image, brightness uniformity in the far and close walls, and decrease of the gain in the central area to avoid artifacts in the vessel lumen.

The patient was placed in the supine position with extension of the neck. The image was taken in the longitudinal view, placing the transducer in the neck, in lateral projection, at the level of the thyroid gland, with the reference mark in the cephalic direction, the ultrasound beam perpendicular to the vessel, to visualize the carotid tree: common carotid artery (CCA), bulb, external carotid artery (ECA) and internal carotid artery (ICA). The walls of the CCA, the bulb and the ICA were explored on each side, right and left, horizontally, to achieve the best interface between the blood and the vascular structures.

In order to measure the CIMT, the image was frozen in the end-diastole guided by the electrocardiographic record, thereby avoiding confusion of the pulsatile deformation of the arterial wall. The calculation of the CIMT was made on the far wall of the CCA, bulb and ICA, with automatic edge detection, between the luminal border of the artery and the border between the media and the adventitia, at 10 mm in length, where the 150 pro-mediated measurements of the CIMT were made, in a short period of time, with the employment of the QLab program of the ultrasound equipment Philips iE33.

In the measurement of the CIMT, the thickness of the atheromatous plaques may or may not be included. This procedure was performed by a single researcher, without information on the results of the angiographic evidence.

Coronary angiography protocol

In order to carry out the diagnostic procedure, the classic techniques of arterial approach were used: femoral (puncture), radial (puncture) or right brachial (dissection).

There was used an equipment Integris HM3000 of Philips Medical Systems, Nederland. Its quantification program was used in the quantitative coronary angiography. The images obtained were stored on hard and compact disks.

The ionic iodinated contrast (76% urografin manufactured by the Schering Company) was used in amounts of 3 to 8 ml per injection, and usual heparin doses during the procedure.

Statistical analysis

The medical records of the admitted patients were

used to obtain all the necessary information, and the Statistical Package for the Social Sciences (SPSS), version 15.0, as a statistical instrument. The qualitative variables were expressed in frequency and percentage, and the continuous quantitative variables, in mean \pm standard deviation or mean and interquartile range, according to their distribution.

The nonparametric U Mann-Whitney test and the Pearson's correlation were used to compare and determine the association of two groups of continuous variables, according to the characteristics of their distribution. It was taken as confidence interval 95%, with a $p < 0.05$ for accepting and interpreting the results.

The sensitivity and specificity of the CIMT for the detection of significant coronary heart disease were evaluated using ROC (Receiver Operating Characteristic) curves. Also, positive and negative predictive values for each of the noninvasive methods of atherosclerosis were calculated, as well as the ratio of positive and negative likelihood, in order to evaluate the safety of such tests.

RESULTS

In the study, the male sex predominated, which represented more than half of the patients studied. The average age of the research patients was 60 years, with a standard deviation of 9.8 years (minimum of 45 and maximum of 78 years).

In patients with heart valve diseases, approximately 11% showed significant coronary lesions, which was more common in those with aortic stenosis (**Table 1**).

The values of CIMT obtained in the CCA and in the bulb of patients with significant coronary lesions were greater than in the group without lesions. Nevertheless, those referred in the ICA did not behave in the same way. The CIMT-CCA values for patients with lesions had as median 0.87 mm, while those obtained in the bulb for this group of patients were 0.75 mm (**Figure 1**).

When determining the association of the CIMT values in each one of the segments studied with the presence of lesions in the coronary arteries, a significant relationship was obtained corresponding to all the contrasted groups (**Figure 2**).

In 47% of patients with CIMT-CCA greater than 0.71 mm, finally the presence of significant coronary stenosis was found; whereas in patients with figures below this cut-off value, the 97% were effectively

Table 1. Distribution of patients according to type of valve and coronary heart diseases.

Valve diseases	Coronary angiography				Total	
	With SL		Without SL		Nº	%
	Nº	%	Nº	%		
Aortic stenosis	5	8.1	18	29.0	23	37.1
Aortic failure	1	1.6	7	11.3	8	12.9
Mitral stenosis	1	1.6	6	9.7	7	11.3
Mitral failure	2	3.2	15	24.2	17	27.4
DVL	-	-	7	11.3	7	11.3
Total	9	11.3	53	88.7	62	100

DVL, double valvular lesion; SL; significant lesion.

Table 2. Value of the carotid intima-media thickness by segments, according to their cut-off values.

Diagnostic test	CIMT-CCA (CV 0.71 mm)	CIMT-Bulb (CV 0.87 mm)	CIMT-ICA (CV 0.98 mm)
Sensitivity (%)	88.5	85.5	14.5
Specificity (%)	83.2	75.2	95.4
Positive PV(%)	47.7	30.6	26.6
Negative PV(%)	97.3	97.4	89.4
Positive LR	5.26	3.4	2.8
Negative LR	0.13	0.2	0.9
Validity index	0.72	0.69	0.09

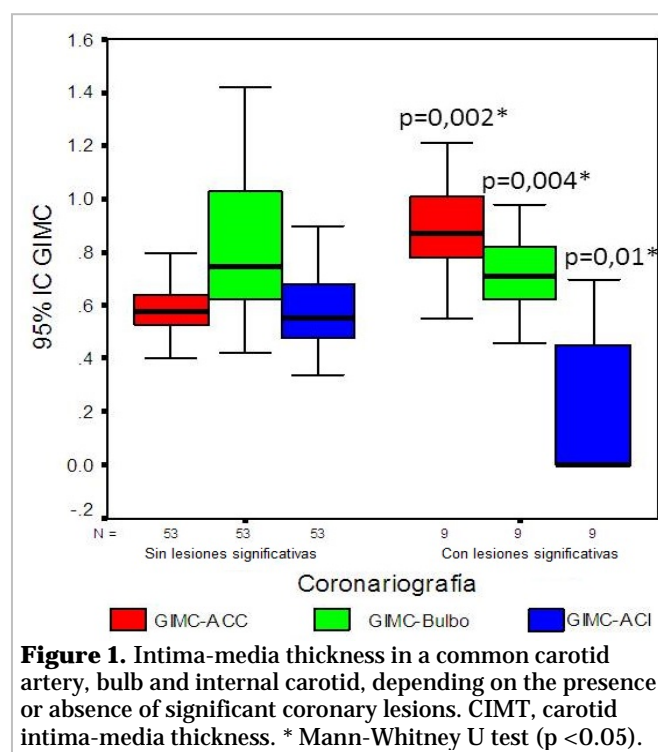
CV, cut-off value; LR, likelihood ratio; PV: predictive value

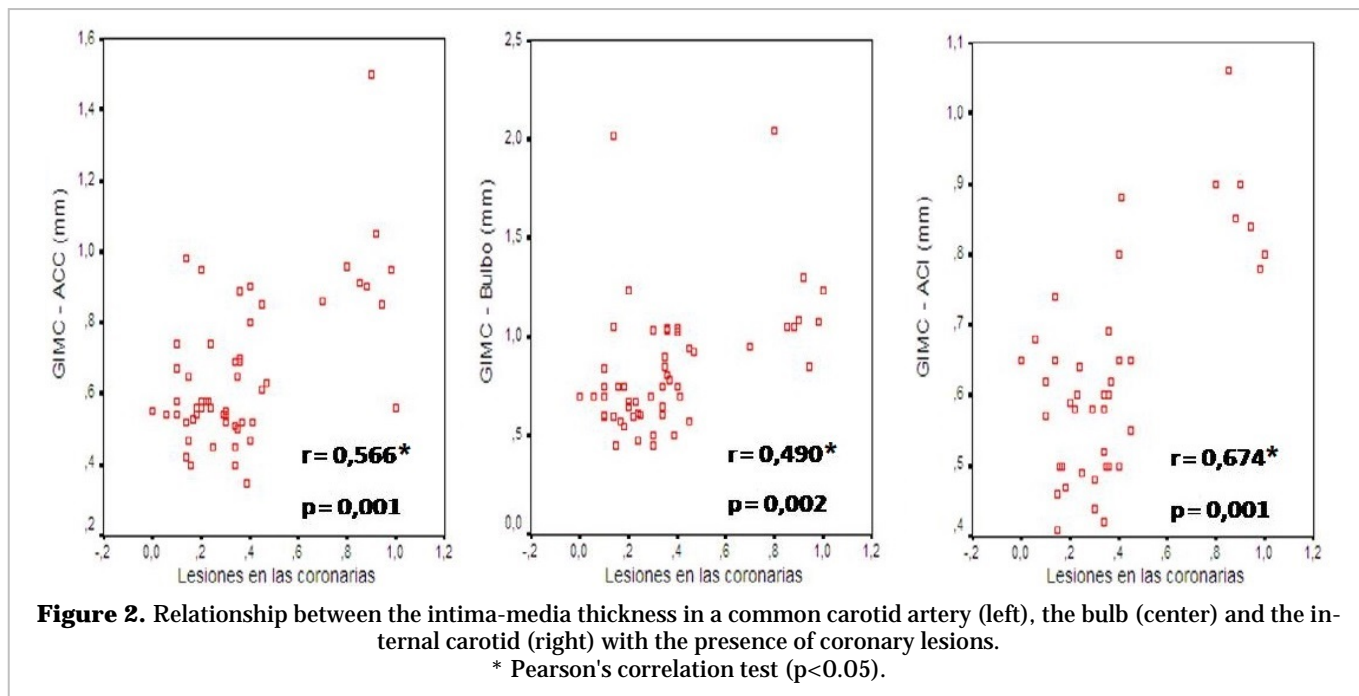
healthy. A CIMT output greater than 0.71 mm in this segment is, therefore, five times more likely in a patient with significant coronary stenosis than in one with normal coronary arteries.

On the other hand, of the patients with CIMT values less than 0.87 mm at the bulb, 97% were in fact healthy. Thus, a result greater than 0.87 mm is three times more likely in a patient with significant coronary stenosis than in one with normal coronary arteries. While in 89% of patients with CIMT-ICA greater than 0.98 mm, finally the absence of significant coronary stenosis was found, with a specificity of 95%.

It was also observed that in order to achieve values of similar sensitivity and specificity, a greater cut-off value of the CIMT at the bulb is needed and even more at the ICA, regarding the CCA; therefore, the latter is the most feasible and safe method of the three evaluated.

Due to the negative predictive values and the reasons for negative likelihood in the three cases are near to 100% and 1, respectively, it can be stated that such tests are feasible in samples of low prevalence





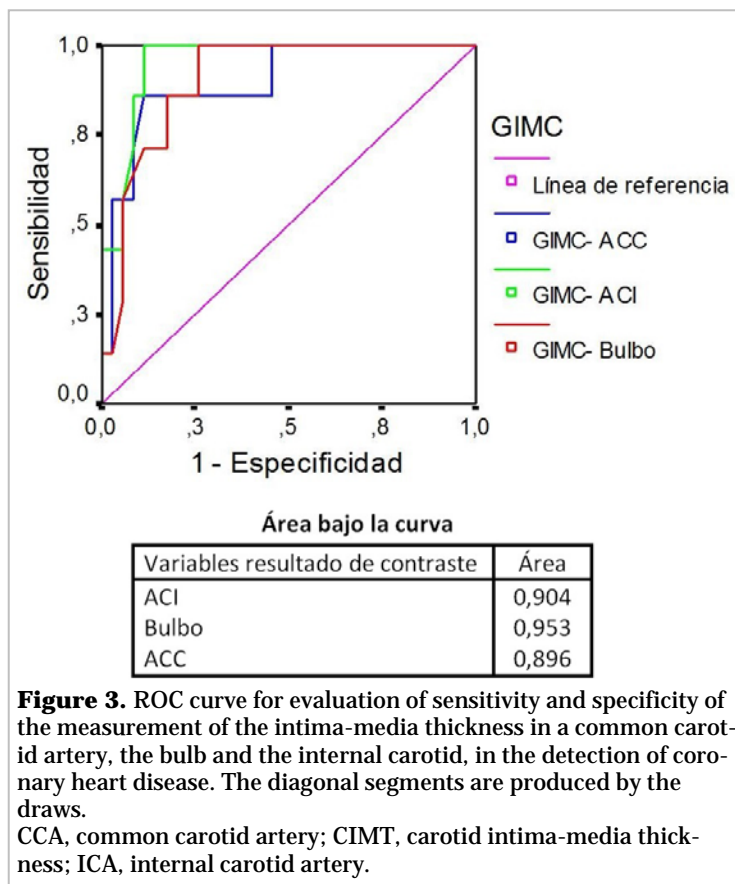
of atherosclerotic disease for detecting healthy patients (**Table 2**).

The results obtained were charted by ROC curves and the areas under the curve were obtained for each of the contrasted variables (**Figure 3**). The determination of the CIMT in the three carotid segments had a value for the detection of lesions in the coronary arteries, because the areas under the obtained curve were close to the unit.

DISCUSSION

Several have been^{15,16} the publications on the prevalence of coronary lesions in patients with heart valve diseases. North American and European studies show figures between 30 and 50%, however, in a work developed by Spanish researchers, these values drop to 10-20%.

Since 2001, at the *Cardiocentro CIMEQ*, the use of the coronary angiography has gradually increased in these patients, related to the rise of the surgical activity corresponding to the valve surgery. The 17% was obtained as prevalence from that date until July 17, 2016, which corresponds with the values obtained in Spanish studies, as re-



ported by Nafeh *et al.*¹⁶. Likewise, in the present study it is similarly, with a value of 11.3%, whether it is considered that the period studied was shorter.

Patients with significant coronary lesions were more frequent in the group with aortic valve diseases. It is well established that the first cause of valve replacement is precisely the aortic stenosis, especially for degenerative causes. It occurs in patients in the later stages of life, precisely where atherosclerotic diseases have a greater presentation. In addition, in patients with aortic valve disease, there are a series of problems with proliferation and inflammatory changes in the aorta, with accumulation of lipids that contribute to increase the risk of suffering from obstructive arterial disease¹⁷.

The above data agree with those found by Gómez Doblas *et al.*¹⁸ in their research, who obtained a prevalence of coronary stenosis of 13.4%, in the population of patients with valve disease. Also, in this same study, higher prevalence of coronary heart disease was found in patients with aortic stenosis compared to other heart valve diseases. This fact has already been detected by other works^{19,20} and it appears linked to age and atherogenic risk factors.

Similar data is also found in the prevalence of coronary lesions in patients with heart valve disease in other articles published on the Iberian Peninsula, which range from 10.7 to 20.3% in the overall set of all heart valve diseases^{21,22}.

The CIMT measurement allows detecting the arterial wall thickening in early stages of the atherosclerosis before the light affection takes place. It has been shown that the CIMT is related to the impact and prevalence of atherosclerosis in all its clinical forms, and also, with the cardiovascular risk factors²³.

Besides, it can be seen that the average values of the CIMT measured in the CCA are greater than those obtained in the bulb and in the ICA, but it is in the bulb and in the proximal part of the ICA that the highest proportion of plaques is found, because they are locations of turbulent flow, not laminar; in addition, the hemodynamic situation is similar to that of the coronary tree (flow separation and shear stress)²⁴. Usually, the CIMT measurement has been used because it is easier and more accurate by the anatomical position of this segment; also, it is known that the atheromatous plaques are presented very few times in this place.

A German regional study showed that the CIMT in the CCA, the bulb and the presence of atheroma-

tous plaques were correlated with the risk of coronary heart disease, but with different degrees of association with the risk factors and with the prevalence of the disease. The CIMT measured in the common carotid was observed more strongly related to the risk factors for stroke, while the CIMT measured in the bulb and the presence of plaques was more directly related with the prevalence of coronary artery disease and its risk factors²⁵.

There are other clinical-therapeutic studies that use the measurement of the CIMT of the CCA plus that of the bifurcation, such as the Kuopio Atherosclerosis Prevention Study (KAPS), and the Beta-Blocker Cholesterol-Lowering Asymptomatic Plaque Study (BCAPS), with similar results^{26,27}.

The study of the combined CIMT is objected to the difficulty of the ICA's visualization, with the possibility of not visualizing any wall and not carrying out a complete evaluation. However, the results of more recent studies show a positive evolution of the measurement at the ICA level, with an increase in its reproducibility from <0.75 to> 0.85. The OPAL study shows a feasibility of viewing all the segments above 90%²⁸.

By correlating the CIMT values in each carotid segments, an association for all tested variables was obtained, being the CIMT-ICA the highest ratio ($r=0.674$), as well as the largest area under the curve, what expresses a possible superiority of this segment with respect to the others, but we cannot forget that the visualization of this segment is very difficult for performing the optimal measurement, and a higher value is needed to obtain adequate specificity, and thus, to be able to rule out the presence of coronary heart disease.

Nonetheless, when calculating the sensitivity and specificity, it was seen that the CIMT measured in the CCA obtained, with a lower cut-off value than the rest of the segments, a better sensitivity; while the negative predictive value was similar for the different studied segments, which corroborates the aforementioned by the works referred to that measuring the CIMT in the CCA is the technique more useful and valid to predict or determine significant coronary heart disease. This fact also is supported in this work when the ROC curves are observed with areas under the curves close to 1.

CONCLUSIONS

The measurement of the carotid intima-media thick-

ness in the three measured segments (common carotid artery, bulb and internal carotid), showed positive correlation with the presence of coronary heart disease, but the data obtained from the common carotid artery were the ones with the most diagnostic accuracy in the patients studied.

REFERENCES

1. Valenzuela A, Morgado N. Breve historia de la relación entre el colesterol y las enfermedades cardiovasculares. *Rev Chil Nutr.* 2006;33(2):130-4.
2. Genest J, McPherson R, Frohlich J, Anderson T, Campbell N, Carpentier A, *et al.* 2009 Canadian Cardiovascular Society/Canadian guidelines for the diagnosis and treatment of dyslipidemia and prevention of cardiovascular disease in the adult - 2009 recommendations. *Can J Cardiol.* 2009; 25(10):567-79.
3. Reiner Z, Catapano AL, De Backer G, Graham I, Taskinen MR, Wiklund O, *et al.* ESC/EAS Guidelines for the management of dyslipidaemias: the Task Force for the management of dyslipidaemias of the European Society of Cardiology (ESC) and the European Atherosclerosis Society (EAS). *Eur Heart J.* 2011;32(14):1769-818.
4. Ministerio de Salud Pública. Anuario Estadístico de Salud 2011. La Habana: Dirección Nacional de Registros Médicos y Estadísticas de Salud; 2012.
5. Llerena-Rojas LR, Peix-González A, Valiente-Mustelier J. Técnicas de imagen no invasivas en la valoración y la prevención de la enfermedad coronaria. *Rev Esp Cardiol Supl.* 2011;11(E):36-44.
6. Nambi V, Chambless L, Folsom AR, He M, Hu Y, Mosley T, *et al.* Carotid intima-media thickness and presence or absence of plaque improves prediction of coronary heart disease risk: the ARIC (Atherosclerosis Risk In Communities) study. *J Am Coll Cardiol.* 2010;55(15):1600-7.
7. Lahoz C, Mostaza JM. La aterosclerosis como enfermedad sistémica. *Rev Esp Cardiol.* 2007;60(2): 184-95.
8. Velasco del Castillo S, Aguilar Torres R, Paré Bardera JC. Actualización en técnicas de imagen cardiaca: ecocardiografía, resonancia magnética en cardiología y tomografía computarizada con multidetectores. *Rev Esp Cardiol.* 2009;62(Supl1): 129-50.
9. Folsom AR, Kronmal RA, Detrano RC, O'Leary DH, Bild DE, Bluemke DA, *et al.* Coronary artery calcification compared with carotid intima-media thickness in the prediction of cardiovascular disease incidence: the Multi-Ethnic Study of Atherosclerosis (MESA). *Arch Intern Med.* 2008;168(12): 1333-9.
10. Polak JF, Pencina MJ, Pencina KM, O'Donnell CJ, Wolf PA, D'Agostino RB. Carotid-wall intima-media thickness and cardiovascular events. *N Engl J Med.* 2011;365(3):213-21.
11. Chain S, Luciarci HL, Feldman G, Valberdi A. El espesor íntima-media carotídeo, un marcador de aterosclerosis subclínica y riesgo cardiovascular. Importancia de su valoración y dificultades en su interpretación. *Rev Fed Arg Cardiol.* 2005; 34(3):392-402.
12. Simon A, Garipey J, Chironi G, Megnien JL, Levenson J. Intima-media thickness: A new tool for diagnosis and treatment of cardiovascular risk. *J Hypertens.* 2002;20(2):159-69.
13. Hulthe J, Wikstrand J, Emanuelsson H, Wiklund O, de Feyter PJ, Wendelhag I. Atherosclerotic changes in the carotid artery bulb as measured by B-mode ultrasound are associated with the extent of coronary atherosclerosis. *Stroke.* 1997; 28(6):1189-94.
14. Mack WJ, Selzer RH, Hodis HN, Erickson JK, Liu CR, Liu CH, *et al.* One-year reduction and longitudinal analysis of carotid intima-media thickness associated with colestipol/niacin therapy. *Stroke.* 1993;24(12):1779-83.
15. Tang R, Hennig M, Thomasson B, Scherz R, Ravinnetto R, Catalini R, *et al.* Baseline reproducibility of B-mode ultrasonic measurement of carotid artery intima-media thickness: the European Lipidipine Study on Atherosclerosis (ELSA). *J Hypertens.* 2000;18(2):197-201.
16. Nafeh M, Hernández R, Carballo N, Villar A, Guevara L, Chaos N, *et al.* Resultados de la revascularización coronaria en el Centro del Hospital «Hermanos Ameijeiras», en un período de 20 años. *Rev Cubana Cir [Internet].* 2011 [citado 15 Oct 2017];50(1):54-72. Disponible en: <http://scielo.sld.cu/pdf/cir/v50n1/cir05111.pdf>
17. Iscan HZ, Kandemir O, Gol MK, Saritas A, Tasdemir O. Coronary reoperations without the use of cardiopulmonary bypass. *Cardiovasc Surg.* 2003; 11(2):155-8.
18. Gómez Doblas JJ, Jiménez Navarro M, Rodríguez Bailón I, Alonso Briales JH, Hernández García JM, Montiel Trujillo A, *et al.* Coronariografía preoperatoria en pacientes valvulares. Análisis de probabilidad de lesión coronaria. *Rev Esp Cardiol.* 1998;51(9):756-61.

19. Nishimura RA, Otto CM, Bonow RO, Carabello BA, Erwin JP, Guyton RA, *et al.* 2014 AHA/ACC Guideline for the management of patients with valvular heart disease: Executive summary: A report of the American College of Cardiology/American Heart Association Task Force on Practice Guidelines. *Circulation*. 2014;129(23):2440-92.
20. Coskun U, Yildiz A, Esen OB, Baskurt M, Cakar MA, Kilickesmez KO, *et al.* Relationship between carotid intima-media thickness and coronary angiographic findings: A prospective study. *Cardiovasc Ultrasound [Internet]*. 2009 [citado 10 Oct 2017];7:59. Disponible en: <https://www.ncbi.nlm.nih.gov/pmc/articles/PMC2809045/>
21. Carreras F, Borrás X, Pons G, Abadal ML, Auge J, Crexells C, *et al.* Prevalence of coronary artery disease in chronic valvular heart disease. *Eur Heart J*. 1987;8(Supl2):142 [Resumen].
22. Torrents A, Esplugas E, Jara F, Mauri J. ¿Ha variado desde 1980 la indicación de coronariografía preoperatoria en pacientes valvulares? Estudio prospectivo de 300 nuevos casos consecutivos. *Rev Esp Cardiol*. 1988;41(10):586-9.
23. Muñoz San José JC, de la Fuente Galán L, Garcimartín Cerrón I, de la Torre Carpenter M, Bermejo García J, Alonso Martín J, *et al.* Coronariografía preoperatoria en pacientes valvulares. Criterios de indicación en una determinada población. *Rev Esp Cardiol*. 1997;50(7):467-73.
24. Fournier JA, Sánchez-González A, Cortacero JA, Martínez A. Estudio angiográfico prospectivo de la enfermedad arterial coronaria en pacientes con patología valvular crónica severa. *Rev Esp Cardiol*. 1988;41(8):462-6.
25. Lorenz MW, von Kegler S, Steinmetz H, Markus HS, Sitzer M. Carotid intima-media thickening indicates a higher vascular risk across a wide age range: Prospective data from the Carotid Atherosclerosis Progression Study (CAPS). *Stroke*. 2006;37(1):87-92.
26. Naghavi M, Falk E, Hecht HS, Jamieson MJ, Kaul S, Berman D, *et al.* From vulnerable plaque to vulnerable patient – Part III: Executive summary of the Screening for Heart Attack Prevention and Education (SHAPE) Task Force report. *Am J Cardiol*. 2006;98(2A):2H-15H.
27. García Fernández R, García Pérez-Velazco J, Concepción Milián A, Curbelo Cuevas MA, García Barreto D. Diagnóstico incruento de la aterosclerosis por ultrasonido. Estructura vascular grosor íntima-media de la pared arterial. *Rev Cubana Med [Internet]*. 2003 [citado 15 Oct 2017];42(3). Disponible en: http://scielo.sld.cu/scielo.php?script=sci_arttext&pid=S0034-75232003000300008
28. Johnsen SH, Mathiesen EB. Carotid plaque compared with intima-media thickness as a predictor of coronary and cerebrovascular disease. *Curr Cardiol Rep*. 2009;11(1):21-7.