

## Extended posterior vertical axillary thoracotomy

Rodolfo E. Morales Valdés<sup>1</sup>✉, MD; Yoandy López-de la Cruz<sup>2</sup>, MD, MSc; and Rodolfo Morales Mato<sup>2</sup>, MD

<sup>1</sup>Department of General Surgery, Hospital Universitario Arnaldo Milián Castro. Santa Clara, Villa Clara, Cuba.

<sup>2</sup>Department of Cardiovascular Surgery, Hospital Provincial Universitario Cardiocentro Ernesto Guevara. Santa Clara, Villa Clara, Cuba.

*Este artículo también está disponible en español*

### INFORMACIÓN DEL ARTÍCULO

Received: April 18, 2019

Accepted: May 30, 2019

### Competing interests

The authors declare no competing interests

### ABSTRACT

Axillary thoracotomies are among the most described and modified in the history of surgery. Despite the sustained development of video-assisted thoracic surgery, the role of classic thoracotomies in current surgical practice is unavoidable, especially when minimally invasive options are not available. Extended posterior vertical axillary thoracotomy emerged almost 30 years ago from the introduction of innovative modifications to axillary thoracic incisions previously described. An extensive literature review makes it possible to affirm that an axillary thoracotomy, which contains all the distinctive features that the one presented herein, has never been reported before. Its main advantages are discussed in relation to the decrease in the operating time and complications during and after surgery.

**Keywords:** Thoracotomy, Thoracic Surgery, Abscess, Lung, Pneumonectomy

### *Toracotomía axilar vertical posterior extendida*

### RESUMEN

*Las toracotomías axilares están entre las más descritas y modificadas en la historia de la cirugía. A pesar del sostenido desarrollo de la cirugía torácica video-asistida, es ineludible el protagonismo de las toracotomías clásicas en la práctica quirúrgica actual, en especial cuando no están disponibles las opciones mínimamente invasivas. La toracotomía axilar vertical posterior extendida, surgió hace casi 30 años a partir de la introducción de innovadoras modificaciones a incisiones torácicas axilares previamente descritas. Una extensa revisión bibliográfica permite afirmar que nunca antes ha sido informada una toracotomía axilar que contenga al unísono todas las características distintivas que la que ahora se presenta. Se discuten sus principales ventajas en relación con la disminución del tiempo operatorio y de las complicaciones durante y después de la cirugía.*

**Palabras clave:** Toracotomía, Cirugía Torácica, Absceso, Pulmones, Neumonectomía

### INTRODUCTION

According to Fabricio de Acquapendente in *Crisol de la Cirugía* (1676)<sup>1</sup>, Hippocrates was likely to be the first thoracic surgeon who extended his incisions to the lateral region of the thorax (referring to it as axilla or armpit), so axillary thoracotomies should be dated about twenty-three centu-

✉ RE Morales Valdés

Calle Ira N° 67.

Rpto. Osvaldo Herrera. Santa Clara

CP 50100. Villa Clara, Cuba.

E-mail address:

rodolfomv@intomed.sld.cu

ries before the moment officially recognized by contemporary medical history.

Vertical thoracotomies in different areas of the axillary region have always responded to the need and convenience of surgeons. When the American George Ryerson Fowler on October 7, 1893 reported (for the first time in the history of modern medicine) an approach to the thoracic cavity in that anatomical location, in order to decorticate a chronic empyema, he needed to involve the drainage sinus of a pleurocutaneous fistula in his elliptical incision<sup>2</sup>. Eugenio Morelli in 1942 began to use a straight, longitudinal (vertical) incision to perform upper thoracoplasties<sup>3</sup>, presumably with the aim of reducing the parietal time of the previously described thoracotomies. Six years later, Sir Denis John Wolko Browne may have described, the only medium-sized posterior vertical axillary thoracotomy that can be found in surgical books, but seemingly convenient to approach some specific organs of the posterior mediastinum<sup>3</sup>. Finally, in the 1970s, Hurtado Hoyo<sup>4</sup>, Baeza and Foster<sup>5</sup>, among others, described other vertical lateral approaches that basically differed in the extent of the surgical wound.

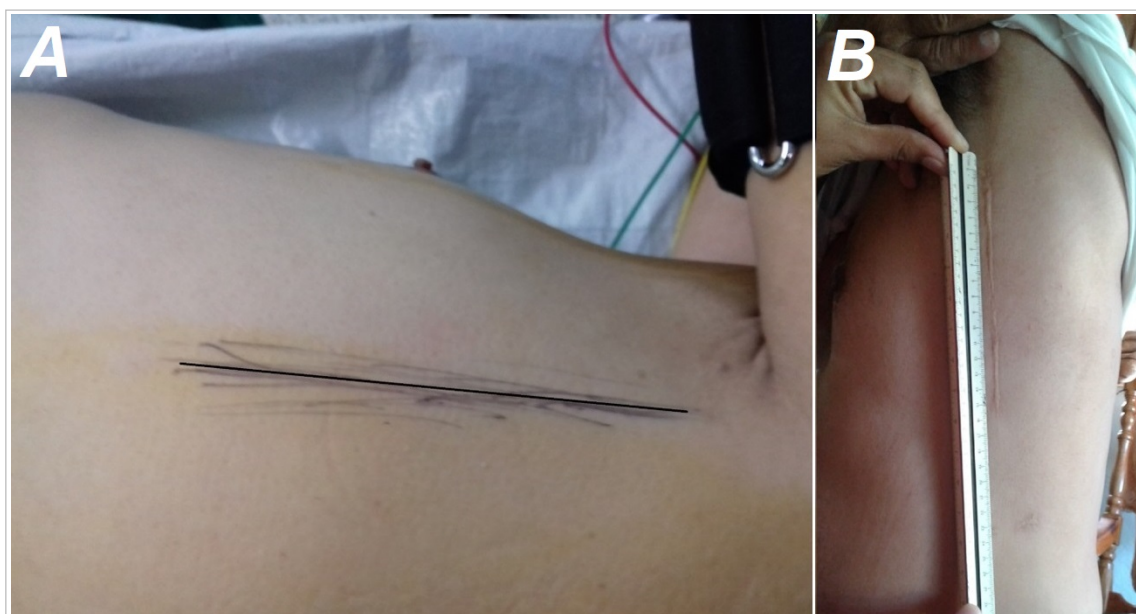
Between 1992 and 1995 the main author of this article devised and perfected a vertical approach to the thoracic cavity by introducing several modifications to previously described longitudinal axillary

thoracotomies. To date, nearly 2000 patients have been operated through this incision, which has allowed for successful treatment of countless thoracic and mediastinal conditions. After almost three decades of experience, an in-depth analysis of the classic descriptions of homologous incisions, allows us to assert that extended posterior vertical axillary thoracotomy presents distinctive characteristics, which make it an innovative method of approaching the pleural cavity, with a myriad of advantages when compared to other thoracic incisions.

### SURGICAL TECHNIQUE

The technique presented here can be performed in almost any patient in whom elective or emergency approach to any organ of the ipsilateral thoracic cavity and to some pathological processes of the mediastinum may be required.

Its distinctive feature is the performance of a variable size-vertical incision (larger than Browne's median and narrower than Hoyo's, depending on the patient's height), along the posterior axillary line which taking the anterior edge of the broad dorsal muscle as a reference, facilitates the surgeon's anatomical orientation (**Fig. 1** and **Fig. 2**). In the parietal phase no type of flap surgery is performed, nor



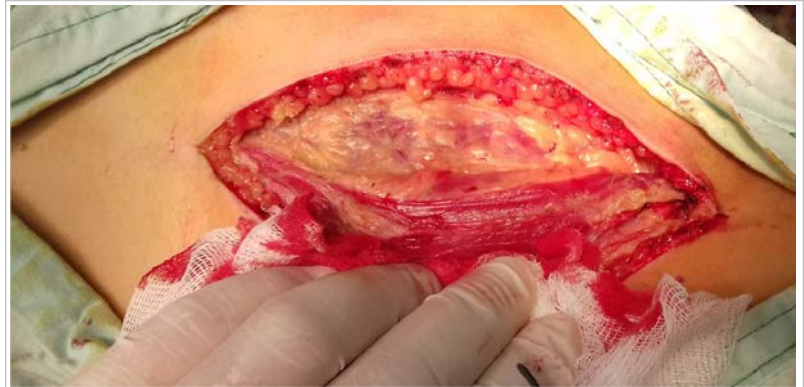**Fig. 1.** Surface anatomical features of the incision. **A.** Location of the incision in the posterior axillary line. **B.** Aesthetic result of a nearly 15 cm length-extended posterior vertical axillary thoracotomy one year after surgery.

are ribs resected, cut or deperiostized.

Patient positioning and preparation are the standards for longitudinal axillary thoracotomies. The skin incision extends from the edge of the axillary hair to the 9th costal arch; deepening in layers, and without developing skin or muscle flaps. Once the serratus muscle vessels have been ligated, this point is taken as a reference to penetrate its fibers by blunt dissection until the 5th intercostal space is accessed and opened (**Fig. 3**) by disinserting the fibers of its muscles along the upper edge of the 6th rib.

It is extremely important that the placement of rib spreaders and the opening of the surgical field coincide with optimal muscle relaxation of the patient, which requires coordinated work with the anesthesiologist. This procedure considerably reduces the incidence of rib fractures and, together with the usual placement of gauze pads on the bone, also helps prevent injury to the subcostal vascular-nervous system (**Fig. 4**).

When surgery has been completed, the thoracic cavity is routinely closed but without the use of a rib contractor to knot the pericostal stitches, since the integrity of the muscular layers, which was practically not modified, greatly facilitates the closure of the intercostal space. This technique does not require submuscular drains at all since the large-flap surgery described in the classical approaches was unnecessary.

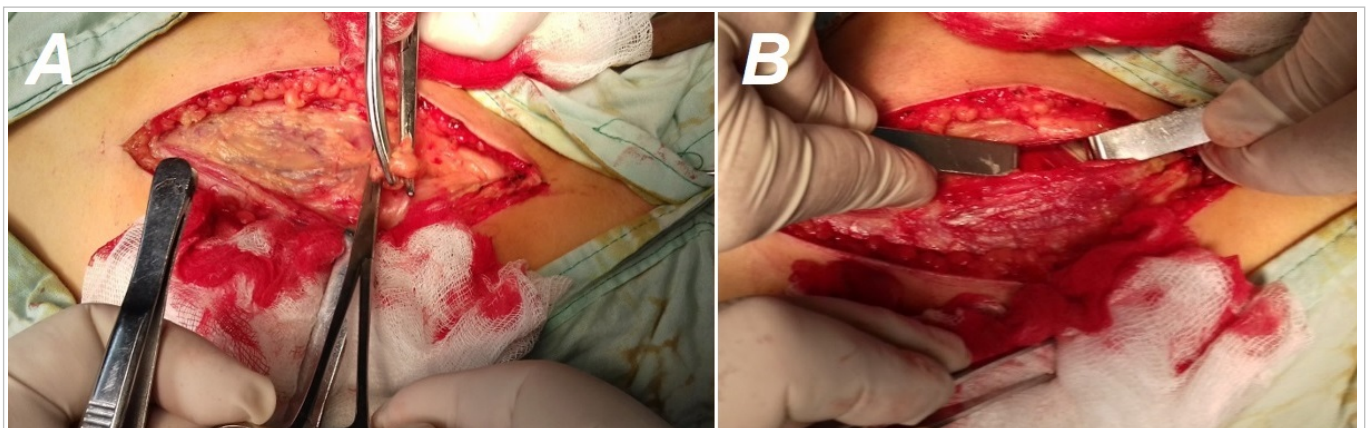


**Fig. 2.** The anterior border of the broad dorsal muscle is used as an anatomical mark for both skin incision and intercostal space approach.

## DISCUSSION

A common feature of most thoracotomies, and especially muscle sparing ones, is the creation of muscle or skin flaps of greater or lesser extension, which allow the mobility required for muscle retraction<sup>6</sup> and facilitate a less traumatic mechanical opening of the intercostal space chosen to access the chest cavity<sup>7</sup>. Thus, logic seems to indicate that most vertical axillary thoracotomies have been described in the vicinity of the midline simply because such convenient performance of the equidistant incision to the spine and sternum may facilitate the development of homogeneous flaps in both directions.

Our technique does not require flap surgery, therefore it does not need to run along the midaxil-



**Fig. 3.** Technical details of the extended vertical posterior axillary thoracotomy. **A.** The site of division (between ligatures) of the serratus muscle vessels, indicates the location to access the chest cavity. **B.** Opening of the intercostal space after cutting (with electrocautery) the superficial insertion of its muscles.



**Fig. 4.** Optimal state of muscle relaxation, padded ribs and placement of two rib spreaders, allow for a wide operating field to access practically any intrathoracic structure.

lary line since the incision is performed in the posterior line, taking the anterior border of the broad dorsal muscle as an anatomical reference. It should be remembered that the incision in the posterior axillary line offers considerable aesthetic advantages when compared to those located in more anterior regions<sup>3</sup>.

Furthermore, in recent years, a growing group of patients<sup>8,9</sup>, with previous coronary artery bypass grafting with subsequent indication of thoracic surgery for generally one or another oncological cause, have been quite benefited from this type of surgical approach. In these cases, access through the posterior axillary line allows avoiding the inconvenience caused by permeable grafts of the internal mammary artery or by anatomical changes in the antero-lateral region, typical of a previously broken and punctured pleural cavity during cardiovascular surgery.

The authors' experience has shown that incisions between 15 and 20 cm long are enough to achieve the desired surgical goals in most patients. Achieving deeper muscle relaxation during the placement

and opening of rib spreaders is a pivotal element since it not only reduces the risk of known skeletal injuries in this surgical phase<sup>10</sup>, which in the vast majority of cases brings about further postoperative pain<sup>11,12</sup>, but also allows for ample expansion of the intercostal space and the creation of a surgical field long enough to facilitate the maneuvers of surgeons during the hilar phase.

Muscle flap or dermal surgery is undoubtedly one of the most important and complex moments in most thoracotomies. Partially removing the muscle framework that protects and holds the ribcage together obviously facilitates the mobility of the ribs and the opening of intercostal spaces, but certainly implies a longer surgical time, more consumption of blood products and risk of postoperative complications at the addressed surgical site<sup>10</sup>.

For this reason, discarding the wide muscle flap surgery so characteristic of almost all classic axillary thoracotomies (in addition to posterior axillary line approach) is considered the most distinctive feature of this technique. This has made it possible to considerably reduce the duration of the surgery and show negligible figures of chest wall-related morbidity and use of blood transfusions; aspects that constitute the subject of further publications.

Apart from the time spent in the hilar phase (related to the complexity of the surgery), the delay both in preparing the entrance to the cavity (flaps), and in placing the submuscular drainage, inevitably prolongs the total duration of similar interventions, when compared to ours.

The reduction of surgical time in thoracic surgery is of great importance in the perioperative outcome of the patient. A causal relationship between the duration of surgery and the appearance of trans or postoperative complications has been demonstrated, particularly those related to cardiac arrhythmias<sup>13</sup>, the use of blood products<sup>14</sup>, prolonged mechanical ventilation times<sup>15</sup> and the abolition of natural lung/airway protection mechanisms, among others.

Incision closure is also an important moment in thoracotomies since the ability of the surgeon in this phase will reduce the duration of the intervention<sup>16</sup>. Avoiding flaps will make it possible to preserve most of the muscular anatomical integrity in the region, thus facilitating natural closure of the intercostal space without the need for rib contractors, which may damage the intercostal vascular-nervous system. The intercostal nerve injury is one of the main causes of post-thoracotomy pain<sup>17</sup> which, in turn, is a major etiopathogenic element in the development

of respiratory complications over this period<sup>18</sup>, since it decreases the depth of breathing and reduces the ability to cough, which dramatically increases the risk of atelectasis and pneumonia<sup>19</sup>.

Unlike other muscle sparing thoracotomies<sup>20,21</sup>, the possibilities of seromas and hematomas in the submuscular planes are practically non-existent, thus avoiding the need for drainage or postoperative aspiration and consequently favoring a faster recovery of the patient and decreasing the risk of infections (abscesses at the surgical site), foreign body retention and fistulas (important in cancer patients with previous radiotherapy)<sup>22</sup>, among other complications<sup>23</sup>; All of which obviously leads to a shorter hospital stay.

## CONCLUSIONS

The extended posterior vertical axillary thoracotomy, highly conservative of the thoracic anatomy, respects the integrity of the muscular and skeletal planes, which allows to increase the benefits of the longitudinal lateral incisions and considerably reduce the incidence of surgical approach-related complications. In scenarios where access to video-assisted surgery is restricted, any effort to optimize the performance of open thoracotomies will be warmly received. The results of almost thirty years of surgical practice, now allow us to share the experience obtained, being sure that this technique will help to greatly improve the quality of life of patients with surgical chest conditions.

## REFERENCES

1. De Aquapendente F. Crisol de la cirugía. Valencia: Mercaderes de Libros; 1676.
2. Fowler GR. A case of thoracoplasty for the removal of a large cicatricial fibrous growth from the interior of the chest, the result of an old empyema. *Medical Record*. 1893;44(27):838-9.
3. Hurtado Hoyo E. Toracotomías axilares. Buenos Aires: Sánchez Teruelo S.A.; 1984.
4. Alonso A, Couto G. Incorporación Solemne a l'Académie Nationale de Medecine de Francia del Acad Elías Hurtado Hoyo. *Rev Asoc Méd Argent*. 2016;129(1):4-7.
5. Baeza OR, Foster ED. Vertical axillary thoracotomy: a functional and cosmetically appealing incision. *Ann Thorac Surg*. 1976;22(3):287-8.
6. Reed MF. Thoracic Incisions. En: Little AG, Merrill WH, eds. *Complications in Cardiothoracic Surgery: Avoidance and Treatment*. 2<sup>a</sup> ed. Oxford: Blackwell Publishing; 2010. p. 22-52.
7. Parikh DH, Crabbe DC. Thoracic Incisions and Operative Approaches. En: Parikh DH, Crabbe DC, Auld AW, Rothenberg SS, eds. *Pediatric Thoracic Surgery*. London: Springer; 2009. p. 81-92.
8. Wei B, Broussard B, Bryant A, Linsky P, Minnich DJ, Cerfolio RJ. Left upper lobectomy after coronary artery bypass grafting. *J Thorac Cardiovasc Surg*. 2015;150(3):531-5.
9. Kanzaki R, Inoue M, Minami M, Shintani Y, Funaki S, Kawamura T, et al. Outcomes of lung cancer surgery in patients with coronary artery disease: a decade of experience at a single institution. *Surg Today*. 2017;47(1):27-34.
10. Nomori H, Horio H, Suemasu K. Intrathoracic light-assisted anterior limited thoracotomy in lung cancer surgery. *Surg Today*. 1999;29(7):606-9.
11. Chen K, Li Y, Wang J. VATS versus Open Lobectomy for Stage I or II NSCLC. En: Ferguson MK, editor. *Difficult Decisions in Surgery: An Evidence-Based Approach*. 3<sup>a</sup> ed. London: Springer-Verlag; 2014. p. 137-52.
12. Dubray C. How to Study Chronic Postsurgical Pain: The Example of Neuropathic Pain. En: Mick G, Guastella V, eds. *Chronic Postsurgical Pain*. New York: Springer; 2014. p. 3-12.
13. Hodari A, Hammoud Z. Perioperative Arrhythmia Prophylaxis for Major Lung Resection. En: Ferguson MK, editor. *Difficult Decisions in Surgery: An Evidence-Based Approach*. 3<sup>a</sup> ed. London: Springer-Verlag; 2014. p. 125-36.
14. Hu Y, Li Z, Chen J, Li F, Shen C, Song Y, et al. Results of comparing transthoracic device closure and surgical repair with right infra-axillary thoracotomy for perimembranous ventricular septal defects. *Interact Cardiovasc Thorac Surg*. 2015; 20(4):493-8.
15. Klinger RY. Fluid Management in Thoracic Surgery. En: Slinger P, editor. *Principles and Practice of Anesthesia for Thoracic Surgery*. 2<sup>a</sup> ed. Cham: Springer Nature; 2019. p. 357-73.
16. Long H, Tan Q, Luo Q, Wang Z, Jiang G, Situ D, et al. Thoracoscopic surgery versus thoracotomy for lung cancer: short-term outcomes of a randomized trial. *Ann Thorac Surg*. 2018;105(2):386-92.
17. Miyazaki T, Sakai T, Yamasaki N, Tsuchiya T, Matsumoto K, Tagawa T, et al. Chest tube inser-

- tion is one important factor leading to intercostal nerve impairment in thoracic surgery. *Gen Thorac Cardiovasc Surg.* 2014;62(1):58-63.
18. Miyata K, Fukaya M, Itatsu K, Abe T, Nagino M. Muscle sparing thoracotomy for esophageal cancer: a comparison with posterolateral thoracotomy. *Surg Today.* 2016;46(7):807-14.
  19. Komatsu T, Sowa T, Takahashi K, Fujinaga T. Paravertebral block as a promising analgesic modality for managing post-thoracotomy pain. *Ann Thorac Cardiovasc Surg.* 2014;20(2):113-6.
  20. Dumitrescu M, Bobocea A, Cordos I. Muscle sparing lateral thoracotomy: the standard incision for thoracic procedures. *J Clin Invest Surg.* 2017;2(1):60-5.
  21. Loscertales J, Congregado M, Moreno S, Jimenez-Merchan R. Posterolateral thoracotomy without muscle division: a new approach to complex procedures. *Interact Cardiovasc Thorac Surg.* 2012;14(1):2-4.
  22. Zembower TR. Epidemiology of Infections in Cancer Patients. En: Stosor V, Zembower TR, eds. *Infectious Complications in Cancer Patients.* Heidelberg: Springer; 2014. p. 43-89.
  23. Sutton SH. Infections Associated with Solid Malignancies. En: Stosor V, Zembower TR, eds. *Infectious Complications in Cancer Patients.* Heidelberg: Springer; 2014. p. 371-411.