

# Atypical electrocardiographic patterns and invasive strategy in high-risk non-ST-segment elevation acute coronary syndrome

## *Alteraciones electrocardiográficas atípicas y estrategia invasiva en el síndrome coronario agudo sin elevación del segmento ST de alto riesgo*

Rodolfo Vega Candelario , MD; and Junior Vega Jiménez , MD

<sup>1</sup>Department of Cardiology, *Hospital General Docente Roberto Rodríguez Fernández*, Morón, Ciego de Ávila, Cuba.

<sup>2</sup>Department of Internal Medicine, *Hospital Militar Docente Dr. Mario Muñoz Monroy*, Matanzas, Cuba.

Received: May 6, 2020

Modified: July 16, 2020

Accepted: October 5, 2020

También está disponible en español

**Keywords:** Acute coronary syndrome, Electrocardiography, Risk, Therapeutic approaches, Invasive strategy

**Palabras clave:** Síndrome coronario agudo, Electrocardiografía, Riesgo, Conductas terapéuticas, Estrategia invasiva

### To the Editor,

Every year, around 1.7 million people are hospitalized in the United States of America for acute coronary syndromes, of whom three quarters (almost 1.3 million patients) suffer unstable angina or non-ST-segment elevation acute myocardial infarction, and Cuba is not exempt from this statistic<sup>1</sup>.


The appearance of ST-segment or T wave changes during symptoms and their normalization after symptoms disappear is diagnostic of non-ST-segment elevation acute coronary syndrome (NSTEMI-ACS)<sup>1</sup>; however, a normal electrocardiogram (ECG) in patients with chest pain does not exclude the possibility of NSTEMI-ACS. Isolated right ventricular or circumflex artery territory ischemia is not frequently reflected on a 12-lead ECG<sup>1</sup>.

In patients with a history of chronic ischemic heart disease, bundle branch block, left ventricular hypertrophy or pacemakers, there may be alterations in ventricular repolarization that interfere with the proper interpretation of the ECG during an event of chest pain; but more and more aspects related to

this useful diagnostic method and its relationship with the clinical picture, echocardiography, prognosis and the risk of cardiovascular complications are also becoming known<sup>2,3</sup>. Among them are a series of atypical electrocardiographic patterns, some recognized, others recently described, which have the importance of indicating a high risk of complications and death: isolated posterior infarction<sup>4</sup>, the “de Winter” pattern<sup>5,6</sup>, Wellens syndrome<sup>7</sup>, ST-segment elevation in aVR<sup>8</sup>, the Sgarbossa criteria for complete left bundle branch block or pacemaker<sup>9</sup>, and hyperacute T waves<sup>10,11</sup>.

An example, among the many that are seen daily, is that of a 58-year-old patient, with no history of heart or other disease, who after work stress began with intense retrosternal pain, radiating to the jaw and both upper limbs, accompanied by profuse sweating, paleness, vomiting and a feeling of imminent death. Upon his arrival at the hospital, about one hour after the symptoms began, he presented rhythmic heart sounds at 60 beats per minute, blood pressure 120/70 mmHg, and fine crackles in both lung bases.

The ECG indicated the presence of mild ST-segment elevation with a negative symmetric T of V<sub>2</sub>-V<sub>5</sub> (**Figure 1A**), for which the patient was admitted to the intensive care unit with the diagnosis of NSTEMI-ACS and the usual measures were started: rest, non-invasive electrocardiographic and hemodynamic monitoring, dual antiplatelet therapy, low molecular weight heparin, statins, and intravenous nitroglycer-

 R Vega Candelario  
*Hospital Roberto Rodríguez Fernández*  
*Libertad esquina a Zayas s/n*  
*Morón 67210, Ciego de Ávila, Cuba.*  
E-mail address: [rvc\\_50@infomed.sld.cu](mailto:rvc_50@infomed.sld.cu)

in (which had to be suspended due to low blood pressure). Beta-blockers were not used because of the low heart rate. A widening of the QRS in the monitor, and the ECG showed a left bundle branch block (**Figure 1B**), which was transient, followed by ST-segment elevation (**Figure 1C**), also transient (a few minutes), clinically accompanied by persistence of pain, paleness and low blood pressure. Considering this high-risk situation, the dobutamine was included in the treatment and arrangements were made for his transfer, aiming to perform urgent percutaneous coronary intervention.

Meanwhile, a transthoracic echocardiogram was performed, where anteroseptal and posterobasal hypokinesia were found, with signs of ischemia through tissue Doppler imaging (TDI) and a left ventricular ejection fraction of 36%.

The electrical instability continued and significant ST-segment elevation of V<sub>2</sub>-V<sub>6</sub> (**Figure 1D**) and ST-segment elevation in the lower wall (leads II, III, and aVF [**Figure 1E**]) were observed, which quickly disappeared to pass to a pseudonormalized trace (**Figure 1F**).

Troponin, total creatine phosphokinase (CPK) and its MB fraction (CPK-MB) remained normal.

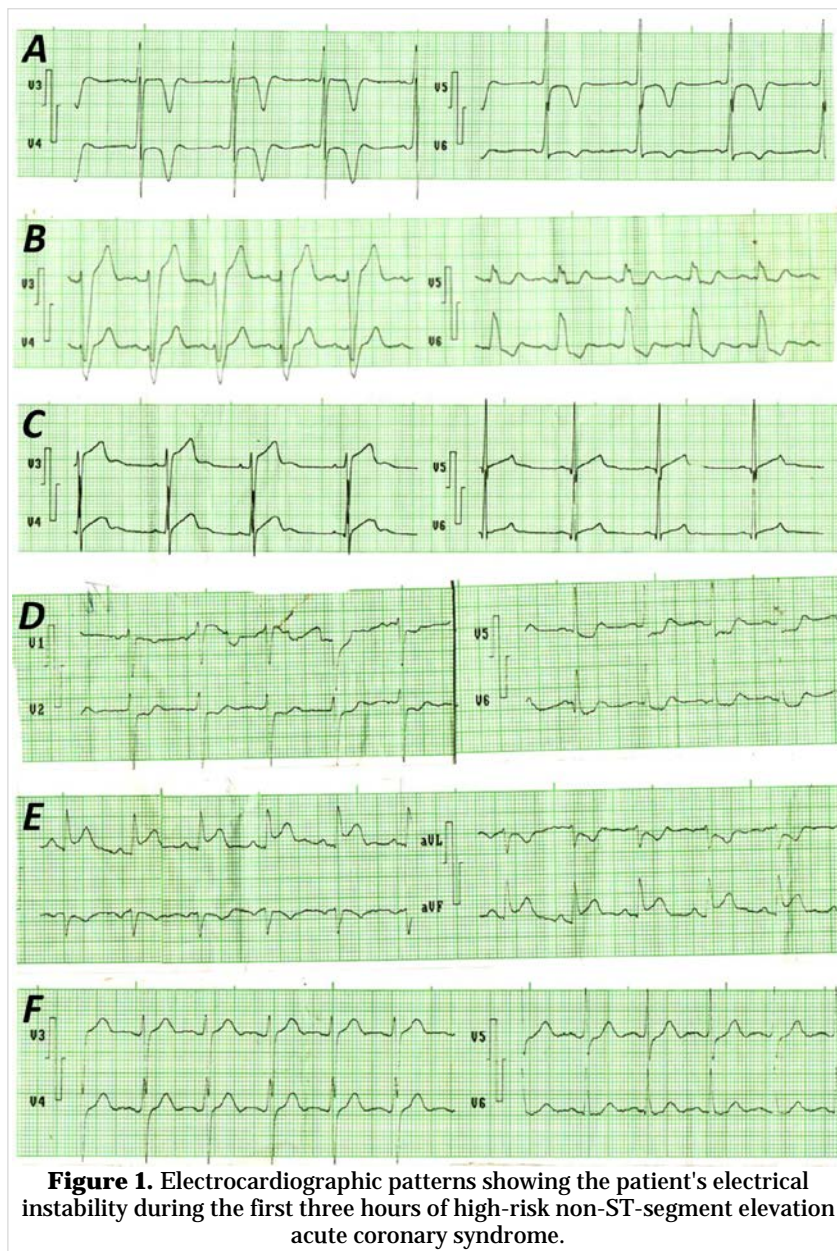
The emergent coronary angiography demonstrated the presence of severe three-vessel disease: two obstructions of 90% and 70% in the proximal and distal segments, respectively, of a dominant right coronary artery (RCA) (**Figure 2A**), 80% in the mid-distal segment of the anterior descending artery (AD) (**Figure 2B**) and 95% of the circumflex (Cx). Two conventional stents were implanted in the RCA (**Figure 2C**), one drug-eluting in the AD (**Figure 2D**), and the Cx was not treated, as it was a non-dominant and small-caliber vessel.

The patient evolved favorably and was discharged without symptoms, 48 hours after the procedure. Cardiac rehabilitation was scheduled, and after three months of acute coronary syndrome; he

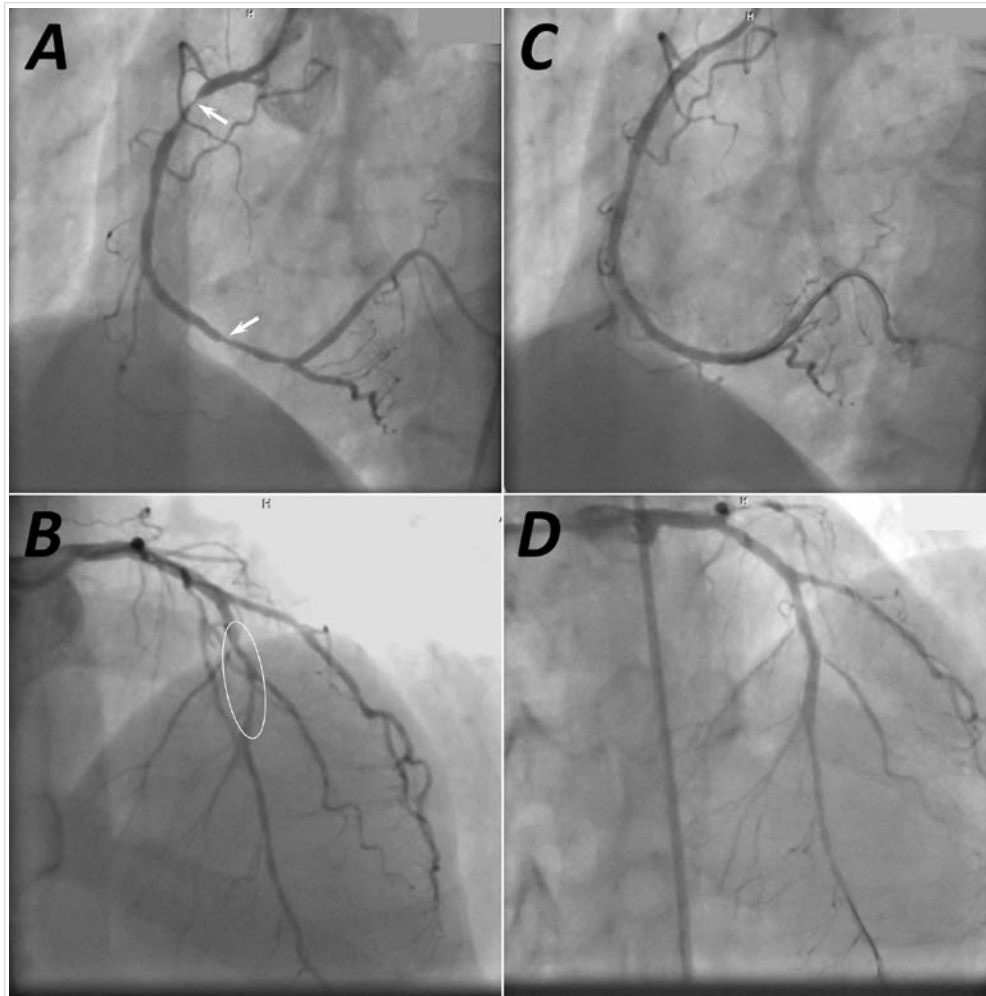
lives a normal active life (he walks 8-10 kilometers a day) and the ergometry is normal.

It is very important that cardiologists, emergency physicians and intensivists recognize these electrocardiographic manifestations, since, typical or atypical, they help us to assess the risk and to make quick decisions and behaviors in order to avoid complications that could compromise the patient's life<sup>10</sup>.

Wellens syndrome and the «de Winter» electrocardiographic pattern, as premonitory signs of complications and sudden death, can occur in the same



**Figure 1.** Electrocardiographic patterns showing the patient's electrical instability during the first three hours of high-risk non-ST-segment elevation acute coronary syndrome.



**Figure 2.** Emergent coronary angiography in a patient with high-risk non-ST-segment elevation acute coronary syndrome. **A.** Dominant right coronary artery with stenosis of 90% and 70% in the proximal and distal segments (arrows), respectively. **B.** Anterior descending line with 80% long stenosis in the mid-distal segment (ellipse). **C and D.** Angiography of both arteries immediately after treating the lesions with stent implantation; note the permanence of the angioplasty guides within the vessels.

patient and it is essential to perform emergency percutaneous coronary intervention to avoid serious ventricular arrhythmias, ST-segment elevation acute myocardial infarction, cardiac rupture and other serious and fatal complications<sup>5-9</sup>.

Patients with ST-segment elevation acute myocardial infarction account for about 30% of all acute coronary syndromes admitted to hospitals. The guidelines of the European Society of Cardiology<sup>13</sup> for its treatment recommend emergency reperfusion in patients with ischemic symptoms and persistent ST-segment elevation, or new left bundle branch block. In the United Kingdom, the primary percutaneous coronary intervention was rapidly imple-

mented as a reperfusion strategy in these patients, requiring the adoption of simple protocols for universal and unequivocal activation of the Interventional Cardiology Department. However, the current practice in that country uses the criterion of ST-segment elevation  $\geq 1$  mm in two or more limb leads, and  $\geq 2$  mm in 2 or more precordial leads, or new left bundle branch block on the ECG, thus that, possibly, the identification of patients with “ST-segment elevation equivalents” fails, which are those who do not present these classic changes in the ECG, but have an acutely occluded coronary artery, which is —often— associated with worse prognoses and results<sup>12-14</sup>.

Therefore, when dealing with a typical clinical picture of chest pain with suspected coronary origin, although the ECG shows atypical alterations or is apparently normal, the possibility of percutaneous coronary intervention should be evaluated, and if echocardiographic signs of acute ischemia are added (disorders of regional motility, TDI) and ventricular dysfunction, the decision should not be delayed, since this delay can have fatal consequences<sup>2,3</sup>.

In Cardiology, good clinical practice, the proper interpretation of electrocardiograms and the support of echocardiography in the acute ischemic patient will help quickly and decisively in the decision-making process to adopt an early invasive strategy in high-risk NSTEMI-ACS<sup>1-11</sup>.

Small details make big differences, therefore, they must be kept in mind, although other complex aspects that are addressed daily are still important.

### **CONFLICT OF INTERESTS**

None declare.

### **REFERENCES**

1. García MR, de Dios Lorente JA. Infarto agudo del miocardio sin elevación del segmento T. Consideraciones fisiopatológicas y clínicas. MEDISAN [Internet]. 2010 [cited Jul 14, 2020];14(4):538-54. Available at: <http://scielo.sld.cu/pdf/san/v14n4/san16410.pdf>
2. Rodríguez Jiménez AE, Cruz Inerarity H, Valdés Arias B, Quintana Cañizares G, Toledo Rodríguez E. Duración del QRS como predictor de baja fracción de eyección en el infarto miocárdico con elevación del ST. CorSalud [Internet] 2018 [cited Jul 14, 2020];10(1):13-20. Available at: <http://www.revcorsalud.sld.cu/index.php/cors/article/view/191/622>
3. Ahumada S, Restrepo G. Ecocardiografía en infarto agudo del miocardio. Rev Colomb Cardiol. 2014;21(3):164-73.
4. Brios e Gala A, Rawlins J. Posterior-wall myocardial infarction. N Engl J Med. 2019;381(17):e32.
5. Barrionuevo-Sánchez MI, Córdoba-Soriano JG, Gallego-Sánchez G, Ramírez-Guijarro C, García-López JC, Jiménez-Mazuecos J. El patrón ST-T de Winter: un equivalente de Síndrome coronario agudo con elevación de ST. Med Intensiva. 2016; 40(2):127-9.
6. Fiol Sala M, Bayés de Luna A, Carrillo López A, García-Niebla J. El «patrón de De Winter» puede evolucionar a síndrome coronario agudo con elevación del segmento ST. Rev Esp Cardiol. 2015; 68(11):1042-3.
7. Kyaw K, Latt H, Aung SSM, Tun NM, Phoo WY, Yin HH. Atypical presentation of acute coronary syndrome and importance of Wellens' Syndrome. Am J Case Rep. 2018;19:199-202.
8. Gibbs MA, Leedekerken JB, Littmann L. Evolution of our understanding of the aVR sign. J Electrocardiol. 2019;56:121-4.
9. Herweg B, Marcus MB, Barold SS. Diagnosis of myocardial infarction and ischemia in the setting of bundle branch block and cardiac pacing. Herzschrittmacherther Elektrophysiol. 2016;27(3):307-22.
10. Valle Alonso J, González Marante CA, Bandera S. Presentaciones electrocardiográficas atípicas en pacientes con síntomas isquémicos, tiempo de cambiar la estrategia. Rev Cuban Cardiol [Internet]. 2017 [cited Jul 15, 2020];23(3). Available at: [http://www.revcardiologia.sld.cu/index.php/revcardiologia/article/view/713/pdf\\_103](http://www.revcardiologia.sld.cu/index.php/revcardiologia/article/view/713/pdf_103)
11. Levis JT. ECG Diagnosis: Hyperacute T Waves. Perm J. 2015;19(3):79.
12. Smith SW. Updates on the electrocardiogram in acute coronary syndromes. Curr Emerg Hosp Med Rep. 2013;1(1):43-52.
13. Ibanez B, James S, Agewall S, Antunes MJ, Bucciarelli-Ducci C, Bueno H, *et al.* 2017 ESC Guidelines for the management of acute myocardial infarction in patients presenting with ST-segment elevation: The Task Force for the management of acute myocardial infarction in patients presenting with ST-segment elevation of the European Society of Cardiology (ESC). Eur Heart J. 2018;39(2):119-77.
14. Rokos IC, French WJ, Mattu A, Nichol G, Farkouh ME, Reiffel J, *et al.* Appropriate cardiac cath lab activation: optimizing electrocardiogram interpretation and clinical decision-making for acute ST-elevation myocardial infarction. Am Heart J. 2010;160(6):995-1003, 1003.e1-8.