

Intermittent atrial tachycardia mimicking atrial flutter

Taquicardia auricular intermitente que simula un flutter auricular

Ciobanu Petre¹, MD; and Ionuț Donoiu²✉, PhD

¹Department of Cardiology, Craiova Cardiology Center. Craiova, Romania.

²Department of Cardiology, Craiova University of Medicine and Pharmacy. Craiova, Romania.

Este artículo también está disponible en español

Key words: Atrial tachycardia, Atrial flutter, Supraventricular tachycardia, Electrocardiography
Palabras Clave: Taquicardia auricular, Flutter auricular, Taquicardia Supraventricular, Electrocardiografía

A 59-year-old woman presented in the emergency department accusing palpitations and chest pain, started two hours prior. She was being treated for hypertension with indapamide and an angiotensin converting enzyme inhibitor, and has had an episode of paroxysmal atrial fibrillation in the last year. The thyroid function was normal six months prior to the admission.

The electrocardiogram at admission (**Figure 1**) showed a sinus rhythm alternating with short bursts of a regular atrial tachycardia with a rate of approximately 300 waves per minute, positive waves in inferior leads, and variable atrio-ventricular conduction. In the first two atrial complexes

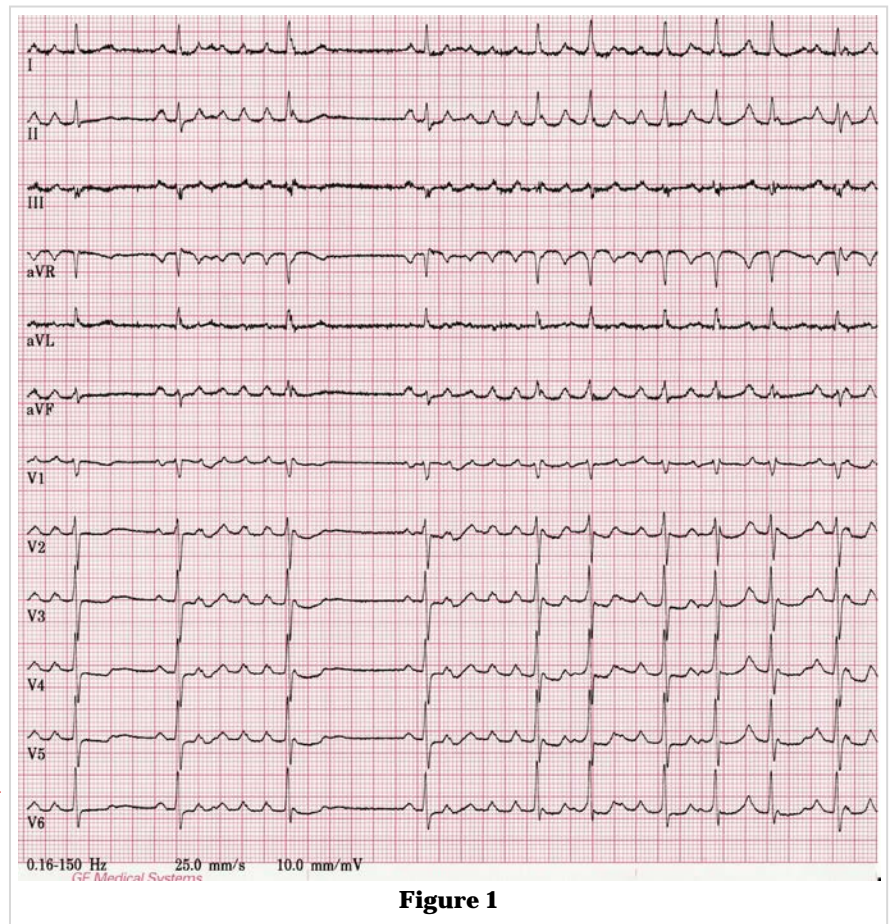


Figure 1

✉ I Donoiu
Department of Cardiology,
Craiova University of Medicine and Pharmacy,
2 Petru Rareș Street, 200349 Craiova, Romania
Correo electrónico: ionut.donoiu@umfcv.ro

there is a slight variation of morphology. The morphology and frequency of the atrial waves mimic an atypical atrial flutter. The patient was initially treated with intravenous metoprolol (a total of 10 mg in the first hour), after which the episodes of tachycardia were progressively shorter and fewer. In **figure 2** we can see that after each sinus P wave conducted to the ventricles follow two premature atrial waves

with the same morphology as in **figure 1**, which are not conducted. Due to the fact that electrophysiological study was not performed, the exact mechanism for the presented arrhythmia could not be established with certainty, but with most probability it was an automatic atrial tachycardia with origin in the upper right atrium (atrial waves are positive in D₁, aVL and inferior leads).

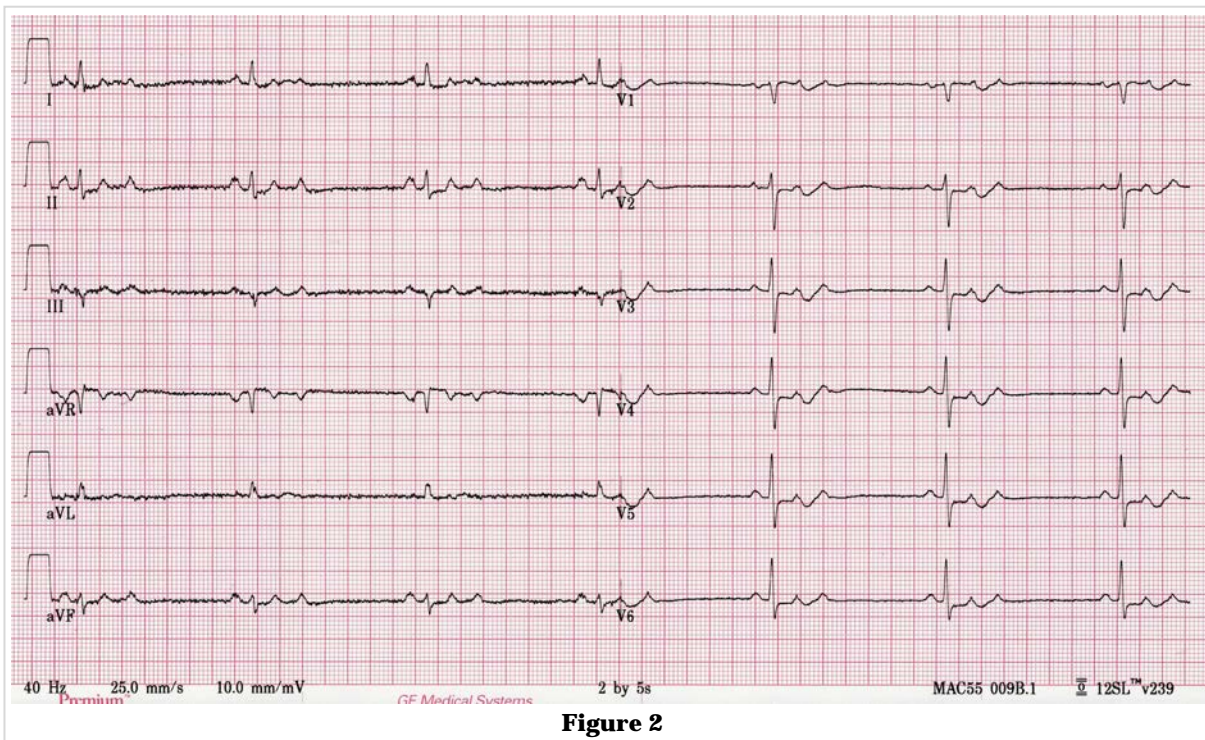


Figure 2