

Aortic dissection as a component of multiple aortic alterations. Case report

Geovedy Martínez García , MD, MSc; Roger Ravelo Dopico, MD; Eliset Valdés Carrazana, MD; Liz O. Cruz Rodríguez, MD, MSc; and Yoanis Cárdenas Fernández, MD

Servicio de Cardiología, Hospital Militar Central Dr. Carlos Juan Finlay. Marianao, La Habana, Cuba.

Este artículo también está disponible en español

ARTICLE INFORMATION

Received: May 21, 2017
Accepted: June 08, 2017


Competing interests

The authors declare no competing interests

Acronym

AD: aortic dissection

On-Line Versions:
Spanish - English

 G Martínez García
Anita 936 e/ Gertrudis y Lagueruela.
10 de octubre, La Habana, Cuba.
E-mail address:
geovedymtnez@infomed.sld.cu

ABSTRACT

The acute aortic dissection is the most common fatal event affecting the aorta and its early mortality is very high. The most common risk factor is high blood pressure, while others are described, like the aortic diseases, traumatismos, and smoking. The case of a 63-year-old patient is described, which had a history of hypertension and who reaches the Emergency Room with severe chest pain spreading to the abdomen and back. A computed tomography angiography was carried out and a DeBakey type IIIb aortic dissection was diagnosed, with extension to the right common femoral artery. There were also diagnosed two congenital malformations: emergency of the left common carotid artery and arterial brachiocephalic trunk from a single common trunk (bovine aortic arch), and a remnant of the ductus arteriosus. After a month of hospitalization, the patient was discharged from the service with clinical stability, awaiting elective surgery.

Key words: Acute aortic dissection, Chest Pain, Congenital Abnormalities, Anatomical variants, Diagnosis

Diseción aórtica como componente de alteraciones aórticas múltiples. Presentación de caso

RESUMEN

La diseción aórtica aguda es el episodio catastrófico más frecuente que afecta a la aorta, su mortalidad precoz es muy alta. El factor de riesgo más frecuente es la hipertensión arterial, aunque se describen otros como las enfermedades de la aorta, los traumatismos y el tabaquismo. Se describe el caso de un paciente de 63 años con antecedentes de hipertensión arterial que llega a Urgencias con dolor torácico intenso con irradiación a abdomen y dorso. Se realizó angiotomografía computarizada y se diagnosticó una diseción aórtica tipo IIIb de DeBakey, con extensión hasta la arteria femoral común derecha. Como hallazgo se diagnosticaron, además, dos malformaciones congénitas: emergencia de la arteria carótida común izquierda y el tronco arterial braquiocéfálico de un solo tronco común (arco aórtico bovino), y un remanente de conducto arterioso. Luego de un mes de internamiento, el paciente fue egresado del servicio con estabilidad clínica, en espera de tratamiento quirúrgico electivo.

Palabras clave: Diseción aórtica aguda, Dolor torácico, Malformación congénita, Variantes anatómicas, Diagnóstico

INTRODUCTION

The aortic dissection (AD) is defined as the rupture of the deepest layer of the aorta, usually caused by an intramural bleeding, which produces separation of this artery wall's layers and consequent formation of a false lumen, besides the true one, with or without communication between them.

Studies of the AD's epidemiology are scarce, some estimated to be approximately 6 per 100,000 persons per year¹. The incidence is higher in men than in women, and it increases with age².

The most frequently associated risk factor is the high blood pressure, generally poorly controlled and found in 65-75% of affected individuals³. Other risk factors include prior aorta or aortic valve disease, family history of aortic disease, smoking, chest trauma, and use of intravenous drugs (cocaine and amphetamines).

CASE REPORT

A 63-year-old man, with a history of high blood pressure without regular treatment, went to the Emergency Department of the *Hospital Militar Central Dr. Carlos J. Finlay*, that in the morning, when he was performing his daily work, started with crushing chest pain irradiating to the back; thus, a presumptive diagnosis of acute coronary syndrome was established. Thirty minutes after his arrival, the patient reported that the chest pain began to irradiate to the abdomen, a fact that radically changed the diagnosis.

With the physical examination were found: rhythmic cardiac noises heart sounds, no murmurs; respiratory rate, 21 breaths per minute; heart rate, 115 beats per minute; blood pressure, 210/110 mmHg, and pain when palpating at the deep epigastrium.

Exámenes complementarios

- Hemochemical: described in the **table**.

Table. Additional blood tests.

Blood tests	Result	Reference values
Hematocrit	0.39	0.42 – 0.52
Leukogram	5.3 x 10 ⁹ /L	4.5 – 10.5 x 10 ⁹ /L
LDH	314 U/L	200 – 400 U/L
Alkaline phosphatase	168 U/L	100 – 290 U/L
GPT	32 U/L	0 – 49 U/L
GOT	32 U/L	0 – 46 U/L
GGT	37 U/L	5 – 45 U/L
Cholesterol	3.97 mmol/l	3.87 – 6.20 mmol/L
Triglycerides	0.72 mmol/L	0.46 – 1.88 mmol/L
Creatinine	87.58 µmol/L	49.0 – 104.0 µmol/L
Uric acid	237 µmol/L	155 – 428 µmol/L
Urea	4.90 mmol/L	3.30 – 8.30 mmol/L
Total proteins	60.3 g/L	60.0 – 80.0 g/L
Albumin	46 g/L	38 – 54 g/L
CPK	239 U/L	24 – 195 U/L
Glycemia	4.73 mmol/L	4.20 – 6.11 mmol/L

CPK: creatine phosphokinase enzyme, GGT: gamma-glutamyl-transpeptidase enzyme, GOT: glutamic oxaloacetic transaminase enzyme, GPT: glutamic pyruvic transaminase enzyme, LDH: lactic dehydrogenase enzyme

- Computed tomography angiography: A double aortic lumen is appreciated, starting from the aortic arch posterior to the emergence of the left subclavian artery, into the common iliac arteries; and on the right side it extends up to the common femoral artery (**Figure 1**). The true lumen shows almost the same density contrast, and it is impressive how the visceral vessels emerge from the true lumen except the left renal artery, that makes it from the false. The left common carotid and the brachiocephalic trunk arise from a common trunk (**Figure 2**). Toward the inferior wall of the aortic arch there is a small addition image, of elongated contour, which is approximately 12-14 mm, that corresponds to the remnant of the ductus arteriosus.

With the clinical picture of the patient and the findings of the questioning and physical examina-

tion, the diagnosing of DeBakey IIIb aortic dissection and type B Stanford was established, with involvement of the left renal artery, despite there is no evidence of renal damage; in addition, a multiple aortic malformation was diagnosed. With this diagnosis, the patient was admitted in the Intensive Coronary Care Unit, where he was stabilized and released a month later. Currently, the patient is awaiting surgery.

COMMENT

The AD represents about 90% of acute aortic syndromes. The intimal alteration results in a dissection plane of the artery's wall that can spread antegrade (or, less frequently, retrograde) through the length of the aorta. It is, at least, twice as common in men, and its real incidence is difficult to know for the pre-

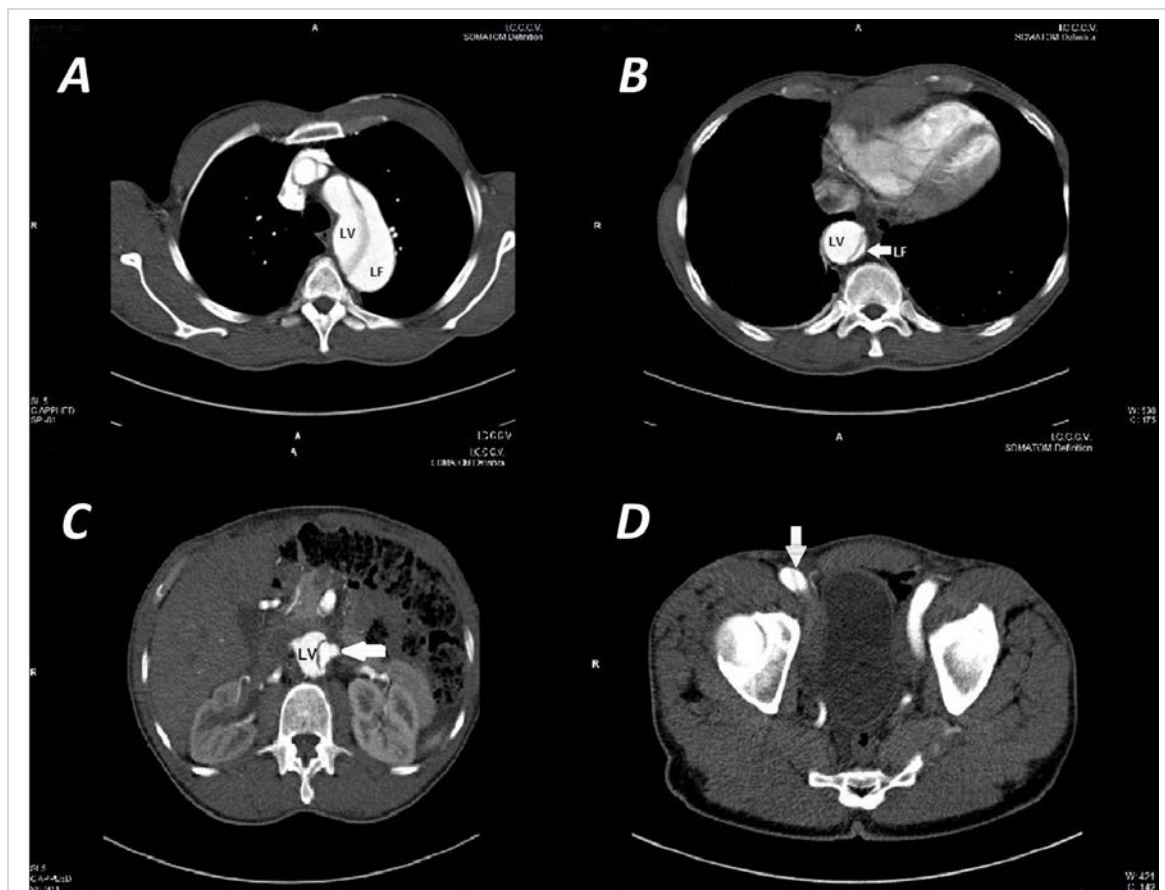


Figure 1. Computed tomography with contrast at different levels, where the aortic dissection is observed after the emergence of supraortic arterial trunks. **A.** Aortic arch. **B.** Descending thoracic aorta. **C.** Abdominal descending aorta at kidneys' level, where the emergence of the left renal artery of the false lumen (arrow) is observed. **D.** Common right femoral artery desiccated (arrow). LF: false lumen (acronym in Spanish), LV: true lumen (acronym in Spanish).

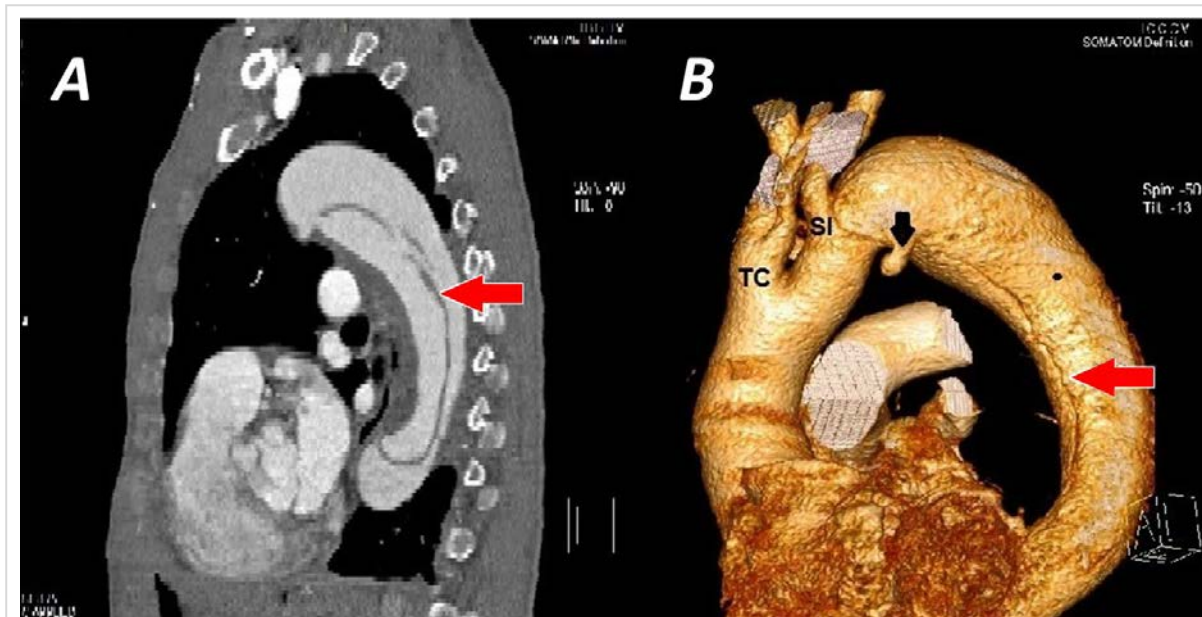


Figure 2. Computed tomography with contrast. **A.** Left lateral view at chest level, where the aortic dissection and intimal flap are observed (arrow). **B.** Tridimensional reconstruction where the emergency of the brachiocephalic arterial trunk and the left common carotid artery of a common trunk (TC [acronym in Spanish]) is observed. The beginning of the dissection (red arrow) after the left subclavian artery (SI [acronym in Spanish]) is also displayed. The black arrow indicates the remnant of the ductus arteriosus.

mature mortality it presents, which makes the diagnosis *in vivo*⁴ impossible in a part of the deceased.

The congenital anomalies of the aortic arch can be varied, from where may result anomalous developments of one or more components of the embryological system of the pharyngeal arch, although there are few reports of aortic arch anomalies secondary to anatomical dissection. These anomalies take place equally in both genders, with no geographic or racial predominance, and the morphological alterations that affect the physiology may be due to tracheal or esophageal compression with clinic importance. A small number of patients have no symptoms until late stages of life and others remain always asymptomatic⁵.

The variant of the aortic arch is most commonly found when it only has two branches and the left common carotid artery arises, together with the brachiocephalic artery, of the aortic arch. It is generally present in 10-13% of patients⁶. This variant has been mistakenly called a bovine aortic arch. It is important to point out that it is wrong because, although called in that way, it does not reflect the real division of aortic arch found in cattle, where what is found is one thick branch derived from the aortic arch. The correct name proposed is common origin of innomi-

nate artery and left common carotid artery, a variant that has found more prevalence in black people (25% of cases)⁷.

Although the anatomical variants are not among the predisposing factors for AD, the presentation of this case is interesting because three anomalies of this type in this large artery had not been described in the same individual; that would have gone unnoticed if the tomography had not been performed.

REFERENCES

1. Howard DP, Banerjee A, Fairhead JF, Perkins J, Silver LE, Rothwell PM. Population-based study of incidence and outcome of acute aortic dissection and premorbid risk factor control: 10-year results from the Oxford Vascular Study. *Circulation*. 2013;127:2031-7.
2. Olsson C, Thelin S, Ståhle E, Ekbom A, Granath F. Thoracic aortic aneurysm and dissection: increasing prevalence and improved outcomes reported in a nationwide population-based study of more than 14,000 cases from 1987 to 2002. *Circulation*. 2006; 114:2611-8.
3. Di Eusanio M, Trimarchi S, Patel HJ, Hutchison S,

- Suzuki T, Peterson MD, *et al.* Clinical presentation, management, and short-term outcome of patients with type A acute dissection complicated by mesenteric malperfusion: observations from the International Registry of Acute Aortic Dissection. *J Thorac Cardiovasc Surg.* 2013;145:385-90.e1.
4. Braverman AC, Thompson RW, Sánchez LA. Enfermedades de la aorta. En: Bonow RO, Mann DL, Zipes DP, Libby P, Braunwald E, Eds. Braunwald Tratado de Cardiología: Texto de medicina cardiovascular. 9ª ed. Barcelona: Elsevier España; 2013. p. 1324-54.
 5. Layton KF, Kallmes DF, Cloft HJ, Lindell EP, Cox VS. Bovine aortic arch variant in humans: clarification of a common misnomer. *Am J Neuroradiol.* 2006;27:1541-2.
 6. Joliat GR, Dubuis C, Déglise S. Complicated thoraco-abdominal aortic dissection presenting with lower limb ischemia in a patient with bovine arch and arteria lusoria. *Eur Rev Med Pharmacol Sci.* 2017;21:310-2.
 7. Idhrees M, Cherian VT, Menon S, Mathew T, Dharan BS, Jayakumar K. Bovine aortic arch with supra-aortic stenosis. *Indian Heart J.* 2016; 68(Supl 2):S83-4.