

## Conservative surgical approach for the treatment of odontogenic keratocyst

### Abordaje quirúrgico conservador para el tratamiento del queratoquiste odontogénico

Letycia Maria Lopes de Oliveira<sup>1</sup>  
Daniela Cristina Braga de Lima<sup>1</sup>  
Nayara Teixeira de Araújo<sup>1</sup>  
Letícia Resende Davi<sup>1</sup>  
Luiz Fernando Barbosa de Paulo<sup>1</sup>

<sup>1</sup> Federal University of Uberlândia (UFU). Minas Gerais, Brazil.

---

#### ABSTRACT

**Introduction:** The odontogenic keratocyst was recently reclassified in 2017 by the World Health Organization as a cystic lesion of epithelial development derived from the enamel organ or the dental lamina. It shows common characteristics to cysts such as slow and continuous growth; however, it arouses attention for its high aggressiveness and recurrence rate.

**Objective:** To show marsupialization followed by enucleation as a definitive treatment of odontogenic keratocysts.

**Clinical case:** A 63-year-old woman with odontogenic keratocyst on the left side of the mandible, treated by the marsupialization technique followed by enucleation.

**Conclusions:** Although there are various treatment options, the dental surgeon may prefer the conservative method in the approach of the odontogenic keratocyst, because it presents the lowest rate of morbidity and relapse within the standards presented in the literature.

**Keywords:** odontogenic cysts; oral diagnosis; oral surgery; keratocyst.

## RESUMEN

**Introducción:** el queratoquiste odontogénico fue reclasificado en 2017 por la Organización Mundial de la Salud como una lesión cística de desarrollo epitelial, derivado del órgano del esmalte o de la lámina dental. Presenta características comunes a quistes, como crecimiento lento y continuo, sin embargo, llama la atención por su alta agresividad y tasa de recurrencia.

**Objetivo:** describir la marsupialización seguida de enucleación como un tratamiento definitivo para el queratoquiste odontogénico.

**Presentación del caso:** mujer de 63 años con queratoquiste odontogénico en el lado izquierdo de la mandíbula, tratado por la técnica de marsupialización seguido de enucleación.

**Conclusiones:** a pesar de diferentes opciones de tratamientos existentes, el método conservador puede ser el tratamiento de elección del cirujano-dentista en el abordaje del queratoquiste odontogénico, pues presenta la menor tasa de morbilidad y recidiva dentro de los patrones mostrados en la literatura.

**Palabras clave:** quistes odontogénicos; diagnóstico bucal; cirugía bucal; queratoquiste.

---

## INTRODUCTION

An odontogenic keratocyst (OKC) is a cyst derived from the remaining cells of the dental lamina. It was reclassified as a cystic lesion instead of an odontogenic tumor (World Health Organization classification, 2017)<sup>1</sup> mainly because it responds favorably to conservative management and does not require surgical resection.<sup>2</sup>

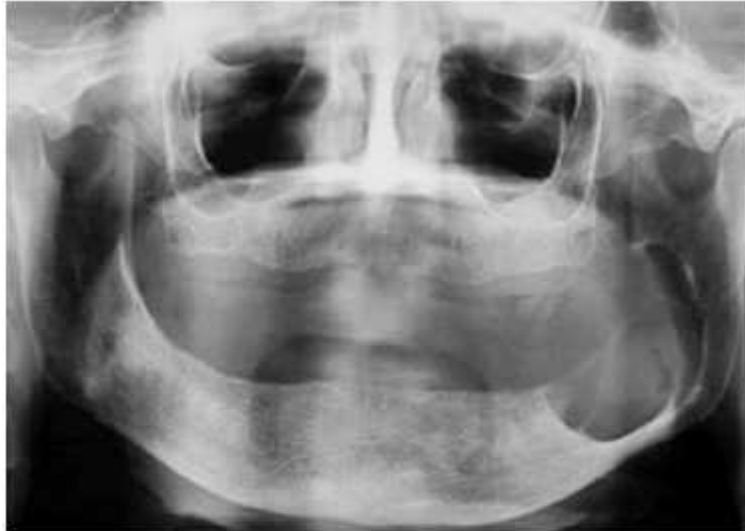
The OKC is the second most common odontogenic cyst, preceded only by dentigerous cysts.<sup>3</sup> It is more prevalent in males<sup>4</sup> and appears mainly in the second and third decade of life. OKCs are most frequently found in the mandible (60 %-80 % of cases) and specifically in the posterior region, in the angle or ascending ramus.<sup>5</sup>

OKC X-rays show unilocular or multilocular radiolucency with well-defined sclerotic margins.<sup>6</sup> The histological characteristics include a fibrous wall devoid of inflammatory infiltrate and an epithelial lining composed of a uniform layer of stratified squamous epithelium. The luminal surface shows flat, irregularly-shaped, parakeratotic epithelial cells.<sup>7</sup>

Generally, odontogenic keratocysts are treated by enucleation using curettage or marginal resection;<sup>5</sup> however, complete removal of the lesion in a single piece is often difficult due to the friable nature of the cystic wall. Thus, large lesions may be treated using marsupialization followed by enucleation.<sup>4</sup> Marsupialization consists of creating a surgical cavity in the cyst wall that allows decompression of the cyst's contents while maintaining continuity between the cyst and the oral cavity.<sup>7</sup> The aim of this case report is to show marsupialization followed by enucleation as a definitive treatment for OKCs and that marsupialization is a crucial step in this approach.

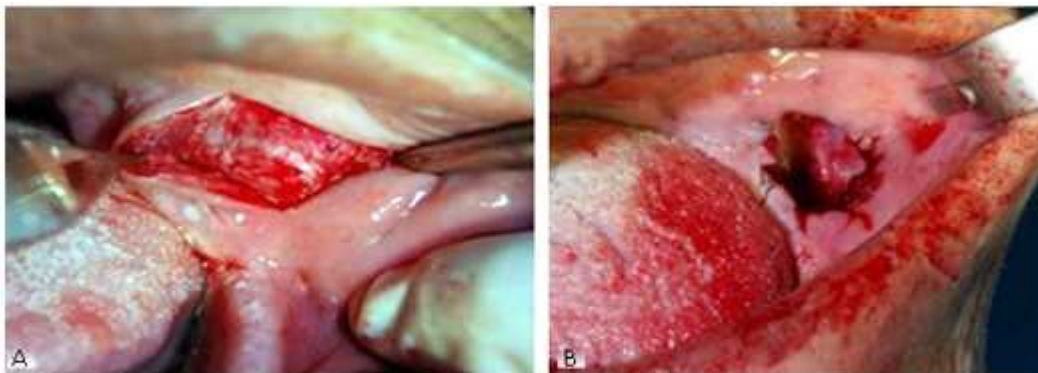
## CASE REPORT

A 63-year-old woman was referred to the Oral Diagnosis Department complaining of oral cavity swelling. Her anamnesis stated that she had been a smoker for 40 years and suffered from hypertension that was controlled by medicine. Clinical examination presented facial asymmetry with slight swelling in the ascending ramus of the left mandible. The intra oral clinical aspect consisted of coloring like that of the oral mucosa, with a tough consistency and no mobility. A panoramic x-ray (Fig. 1) demonstrated an extensive, well-defined unilocular radiolucent lesion with a diameter of 5 cm. A provisional diagnosis of odontogenic keratocysts was made based on the clinical and radiographic aspects.



**Fig. 1.** Panoramic x-ray with an extensive unilocular radiolucent lesion in the left mandible.

An intra-oral incisional biopsy with marsupialization was performed under local anesthesia (Lidocaine 2 % with epinephrine; DFL, Rio de Janeiro-RJ). First, an incision was made in the cheek mucosa (Fig. 2, A) and then a surgical cavity was made in the wall of the cyst. Next, the cyst lining was everted into the cavity and sutured (Nylon suture 5.0, Procure, China) to the adjacent mucosa forming a cavity (Fig. 2, B). This cavity was exposed to the oral environment, which decreased intracystic pressure and consequently reduced the size of the lesion. The cyst was then sent for histopathological examination.



**Fig. 2.** A: Incision in the cheek mucosa showing the cystic wall. B: Cyst lining everted and sutured to the adjacent mucosa.

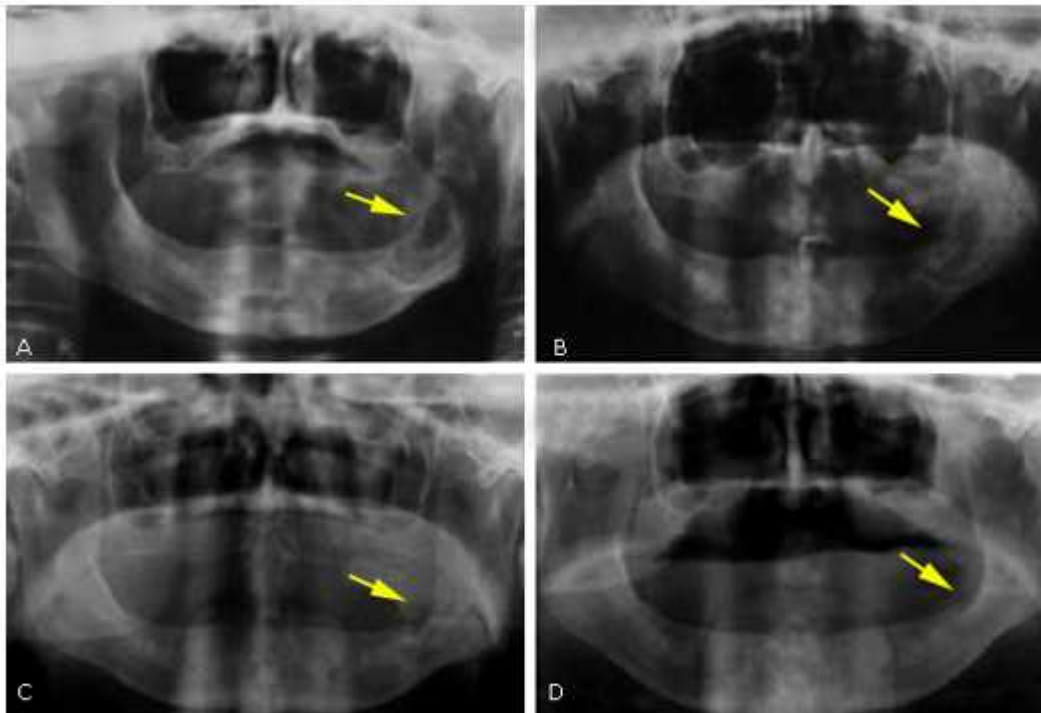
We chose to perform marsupialization followed by enucleation because of the size of the lesion and the position of the cyst capsule, which could have resulted in damage to the inferior alveolar nerve had the resection technique been used. The patient was instructed to follow a diet of soft foods for at least one week and to perform oral hygiene consisting of local irrigation via plastic syringe (0.2 % chlorhexidine), three times per day. An oral antibiotic (amoxicillin 500 mg 1.5 g/day for 7 days) and a non-steroidal analgesic were also prescribed.

A histological exam showed benign odontogenic neoplasia with a cystic structure. The tissue was covered with a parakeratinized stratified pavement epithelium with surface corrugation. The hyperchromatic basal layer featured reverse polarization foci and an interface rectified for connective tissue. The cystic capsule was composed of dense, formless connective tissue that confirmed the provisional OKC diagnosis.

Follow-up panoramic x-rays showed regression of the lesion, resulting from decompression, and bone formation (Fig. 3, A). Nine months after marsupialization, the size of the lesion had regressed sufficiently to perform enucleation surgery (Fig 3, B).

For this surgery, local anesthesia was applied (Lidocaine 2 % with epinephrine; DFL, Rio de Janeiro - RJ), and a horizontal incision was made in the alveolar ridge using a #15 scalpel. This resulted in a mucoperiosteal flap that exposed the cystic cavity. Lucas's bone curette was used to perform curettage and then the cavity was irrigated with saline solution. The flap was then closed with 5.0 nylon sutures (Nylon suture 5.0, Procure, China) and the same medication was prescribed as that used after the marsupialization procedure.

Twelve months after marsupialization (six months after enucleation) the bone defect presented a radiopaque aspect indicating bone deposition (Fig. 3, C). A follow-up examination at 15 months after the enucleation procedure showed no recurrence (Fig. 3, D). The patient continued to be monitored for 6 years.



**Fig. 3.** Follow up by panoramic x-ray, the yellow arrow shows the evolution of bone neoformation, the lesion regression along the time. A: After 6 months of the marsupialization. B: After 9 months the marsupialization treatment. C: After 12 months of the marsupialization. D: After 15 months from the enucleation.

## DISCUSSION

The OKC is a development cyst that most frequently occurs in the mandibular ramus.<sup>8</sup> A similar situation was found in the present study. It is difficult to differentiate OKCs from other cystic lesions of the mandible using x-rays. However, OKCs are unique in that they develop anteroposteriorly within the medullar cavity without generating bone expansion, whereas other large dentigerous and radicular cysts tend to expand the jaws.<sup>5</sup> Nevertheless, a definitive diagnosis can only be made by histopathologic analysis.

Consensus has not yet been reached on the best treatment for OKC. Several treatment options are available<sup>9</sup> including aggressive approaches like lesion resection, and conservative options such as marsupialization, decompression, enucleation and curettage.<sup>8</sup> Several factors determine treatment type including patient age, lesion location and size, and whether the OKC is primary or recurrent.<sup>10</sup> Large lesions should be first marsupialized and then enucleated. According to *Pogrel*,<sup>11</sup> when a lesion, after decompression, reaches approximately 2-3 cm, the OKC can be enucleated. At this stage, the cyst covering becomes more robust, thicker and more like the oral epithelium.

Marsupialization significantly decreases cystic volume and avoids injury to anatomical structures such as the inferior dental nerve.<sup>6</sup> *Telles* and collaborators (2013)<sup>12</sup> evaluated the morphology of the epithelial lining and the fibrous capsule of the OKC and found that marsupialization causes significant changes that facilitate surgical treatment and may be linked to lower rates of OKC recurrence.

OKC recurrence rates are generally high and can reach 60 %.<sup>5,9</sup> However, this rate may depend on treatment type. The most common reasons for recurrence are incomplete removal of the lesion and formation of a new OKC from small satellite cysts.<sup>5</sup> The majority of recurrences appear within 5 years after treatment.<sup>13</sup>

*Habibi et al.*<sup>14</sup> performed a retrospective analysis of patients diagnosed and treated for OKC at the Mashhad School of Dentistry between 1996 and 2006. They found that patients treated with either enucleation or marsupialization alone had recurrence rates of 7.6 % and 33.3 %, respectively, while those treated with marsupialization followed by enucleation had no recurrences. *Castro et al.*<sup>6</sup> showed in a systematic review and meta-analysis that the decompression or marsupialization followed by enucleation are the conservative treatments with the lower recurrence rate (11,9 % and 17,8 % respectively), when comparing with enucleation alone (20,8 %).

The resection approach usually has a low recurrence rate;<sup>9</sup> nevertheless, this treatment is more traumatic for the patient, and there are many damage that must be pondered, for example, it provides significant morbidity such as the loss of the jaw continuity or facial deformation. <sup>6</sup> Hence, conservative treatments are more frequently recommended.

We showed that marsupialization followed by enucleation can lead to complete regression of an OKC, while being conservative and avoiding damage to vital structures. However, this method requires a longer treatment, multiple procedures and cooperation of the patient. Furthermore, the patients that undergo this surgery must have regular follow-up x-ray examinations for an indeterminate time.

To date, no randomized controlled trials have been undertaken to establish which treatment modality provides the lowest recurrence rate. Further studies are needed to determine the best and safest option.

## Conflicto de intereses

The authors have no conflicts of interest to declare

## REFERENCES

1. El-Naggar AK, Chan JK, Grandis JR, Takata T, Slootweg PJ (eds.). WHO Classification of Head and Neck Tumours. 4th ed. Lyon, France: IARC Press; 2017.
2. Siwach P, Joy T, Tupkari J, Thakur A. Controversies in Odontogenic Tumours. Sultan Qaboos Univ Med J. 2017;17:268-76.
3. Louredo BVR, Freitas CTS, Câmara J, Liborio-kimura TN. Estudo epidemiológico de lesões odontogênicas provenientes do Departamento de Patologia e Medicina Legal da Universidade Federal do Amazonas. Rev Bras Odontol. 2017;74(2):126-132 Access: 02/02/2017. Available from: [http://revodontobvsalud.org/scielo.php?pid=S0034-72722017000200008&script=sci\\_arttext&lng=pt](http://revodontobvsalud.org/scielo.php?pid=S0034-72722017000200008&script=sci_arttext&lng=pt)
4. Martin L, Speight P. Odontogenic cysts. Diagnostic Histopathology. 2015;21:359-369.
5. Waldron CA. Cysts and Odontogenic Tumors. In: Neville BW, Damm DD, Allen CM Bouquot, editors. Oral and Maxillofacial Pathology, 3<sup>rd</sup> ed. New York: WB Saunders Company; 2009 p. 679-733.
6. de Castro MS, Caixeta CA, de Carli ML. Conservative surgical treatments for nonsyndromic odontogenic keratocysts: a systematic review and meta-analysis. Clin Oral Invest. 2018;22:2089-101.
7. de Paulo LFB, Perez DEC, Rosa RR, Oliveira MTF, Durighetto-Júnior AF. Giant facial dermoid cyst: A case treated by marsupialization. Rev Port Estomatol Med Dent Cir Maxilofac. 2014;55:167-70.
8. Molon RS, Verzola MH, Pires LC, Mascarenhas VI, da Silva RB, Cirelli JA, et al. Five years follow-up of a keratocyst odontogenic tumor treated by marsupialization and enucleation: A case report and literature review. Contemp Clin Dent. 2015;6:106-10. Access: 02/02/2017. Available from: <http://www.contemplindent.org/article.asp?issn=0976237X;year=2015;volume=6;issue=5;page=106;epage=110;aulast=de>
9. Cunha JF, Gomes RA, Mesquita RA, Andrade Goulart EM, Castro WH, Gomez RS. Clinicopathologic features associated with recurrence of the odontogenic keratocyst: a cohort retrospective analysis. Oral Surg Oral Med Oral Pathol Oral Radiol. 2016;121:29-635.
10. Varsha B, Gharat AL, Nagamalini B, Jyothsna M, Mothkur ST, Swaminathan U. Evaluation and comparison of expression of p63 in odontogenic keratocyst, solid ameloblastoma and unicystic ameloblastoma. J Oral Maxillofac Pathol. 2014;18:223-8.
11. Pogrel MA. The keratocystic odontogenic tumour (KCOT)-an odyssey. Int J Oral Maxillofac Surg. 2015;44:1565-8.
12. Telles DC, Castro WH, Gomez RS, Souto GR, Mesquita RA. Morphometric evaluation of keratocystic odontogenic tumor before and after marsupialization. Braz Oral Res. 2013;27:496-502. Access: 02/02/2017. Available from: [http://www.scielo.br/scielo.php?script=sci\\_arttext&pid=S1806-83242013000600496](http://www.scielo.br/scielo.php?script=sci_arttext&pid=S1806-83242013000600496)

13. Ebenzar V, Balakrishnan R, Sivakumar M. A case report on surgical management of odontogenic keratocyst. *World J Med Sci* 2014; 10:212-216.

14. Habibi A, Saghravarian N, Habibi M, Mellati E, Habibi M. Keratocystic odontogenic tumor: a 10-year retrospective study of 83 cases in an Iranian population. *Journal of Oral Science*. 2007; 49:229-235. Access: 02/02/2017.

Available from:

[https://www.jstage.jst.go.jp/article/josnurd/49/3/49\\_3\\_229/\\_article](https://www.jstage.jst.go.jp/article/josnurd/49/3/49_3_229/_article)

Recibido: 29/05/2018

Aceptado: 28/07/2018

*Letycia Maria Lopes de Oliveira*. Federal University of Uberlândia (UFU). Av. Pará, 1748 - Umuarama, Uberlândia Minas Gerais, Brazil.

Correo electrónico: [letycialopes257@gmail.com](mailto:letycialopes257@gmail.com)